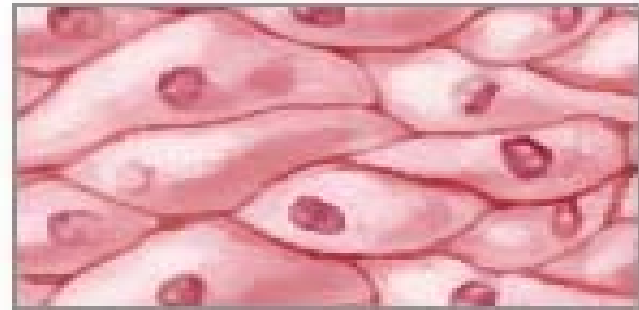


TEJIDOS


Cuatro tipos de tejido



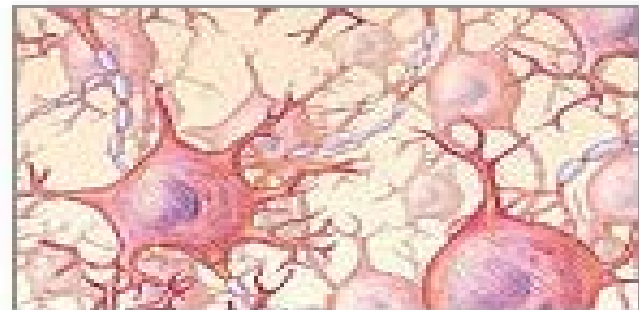
Tejido conectivo



Tejido epitelial



Tejido muscular



Tejido nervioso

TEJIDOS ANIMALES



Tejido epitelial



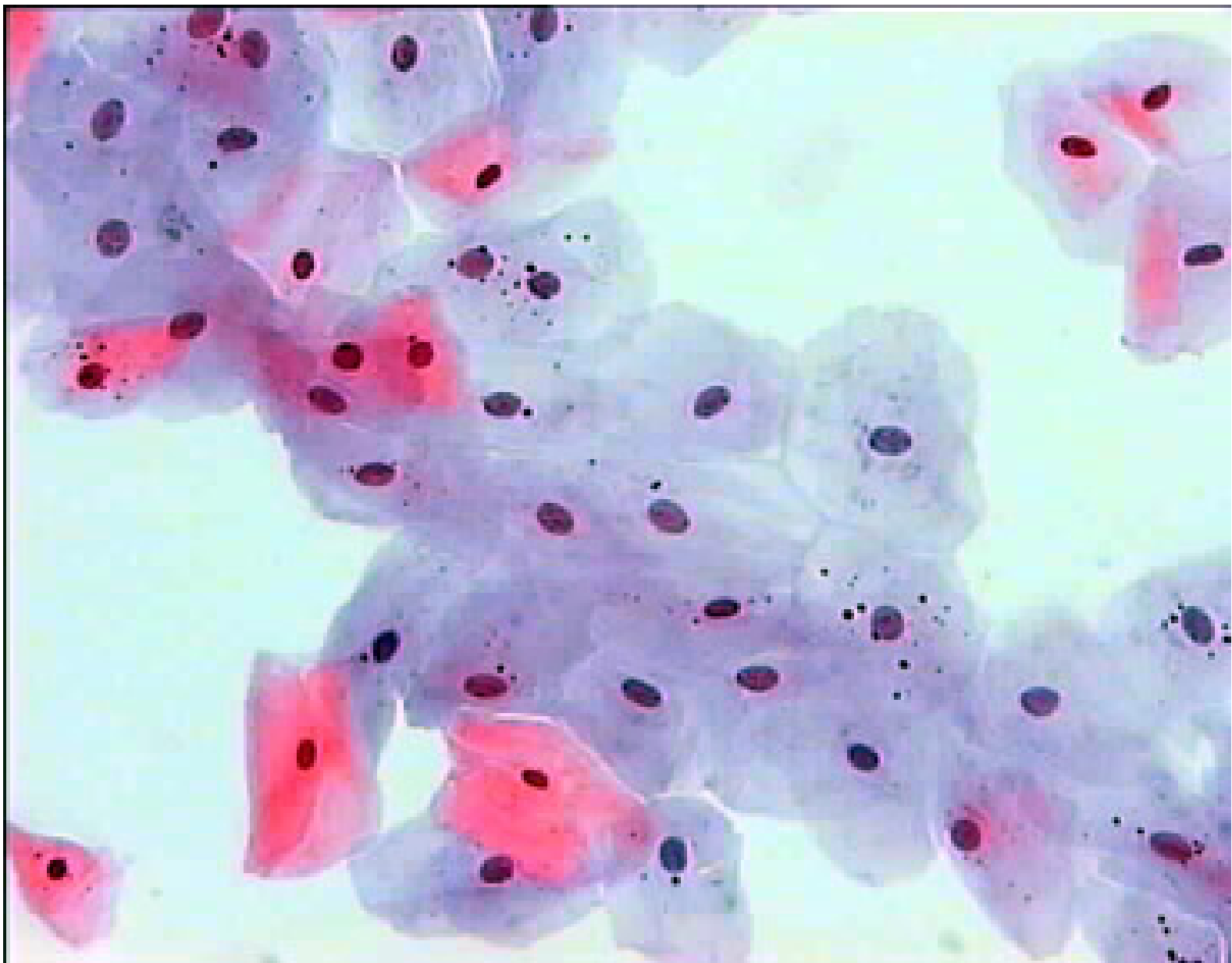
Tejido conectivo

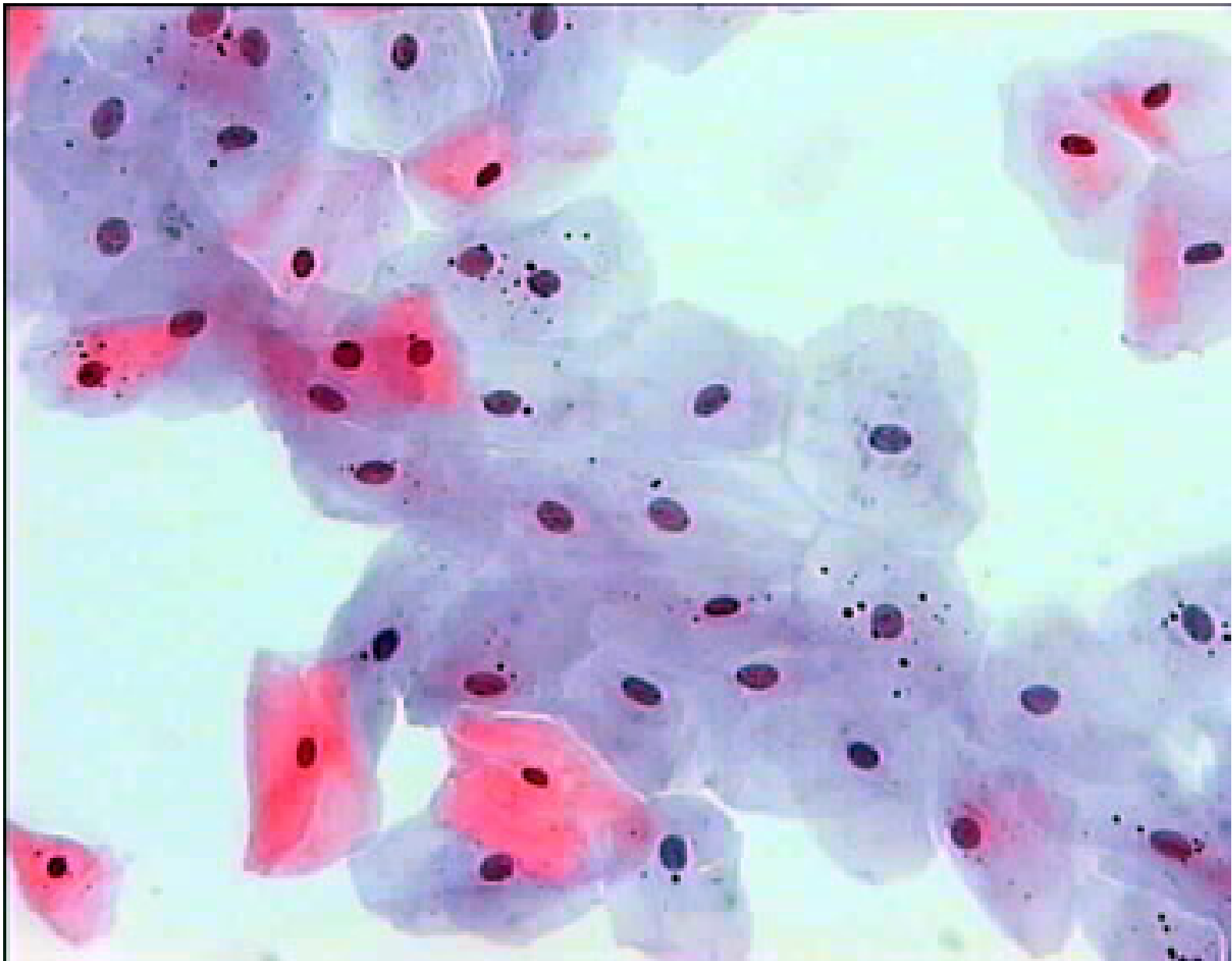

Tejido muscular

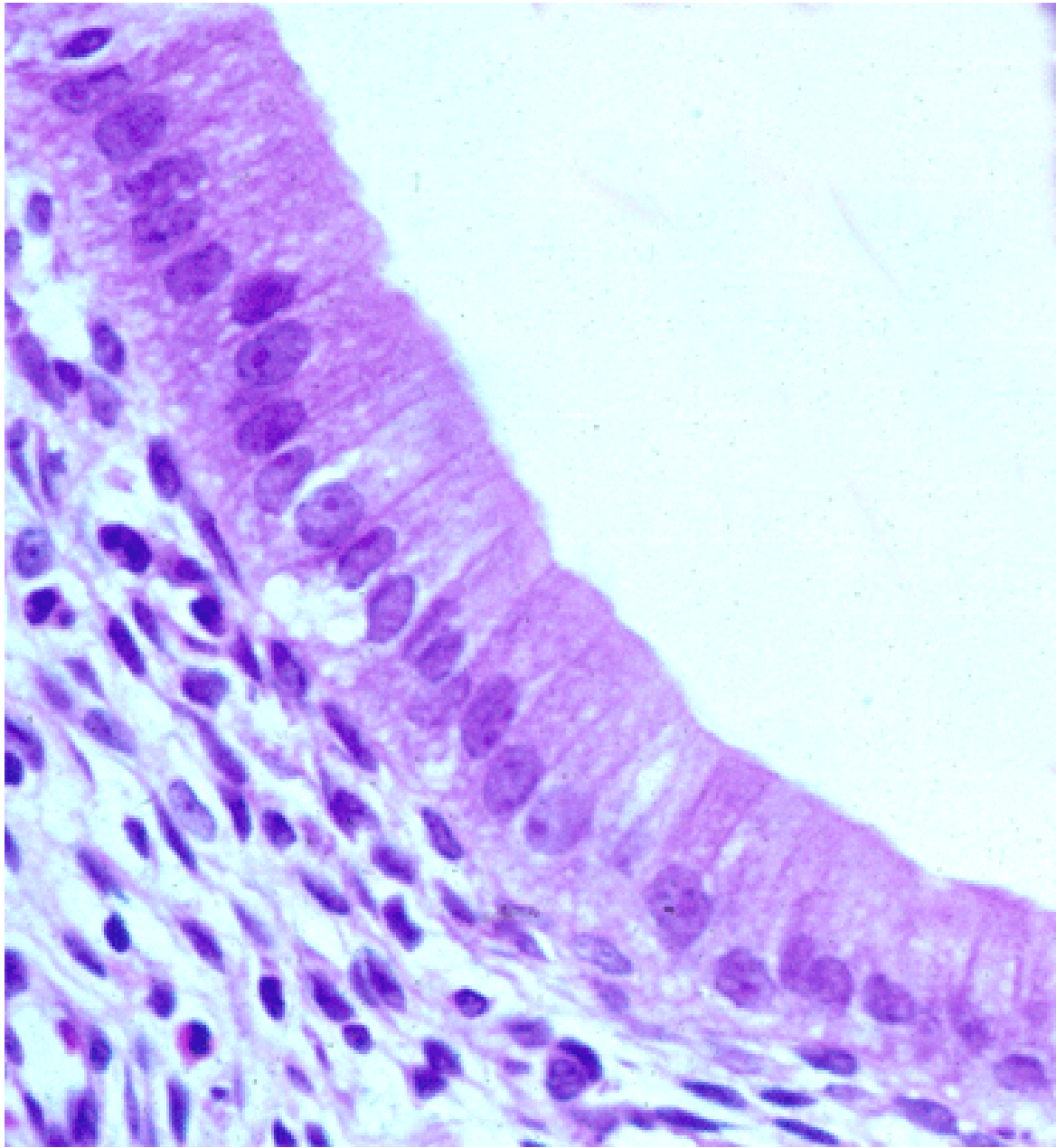


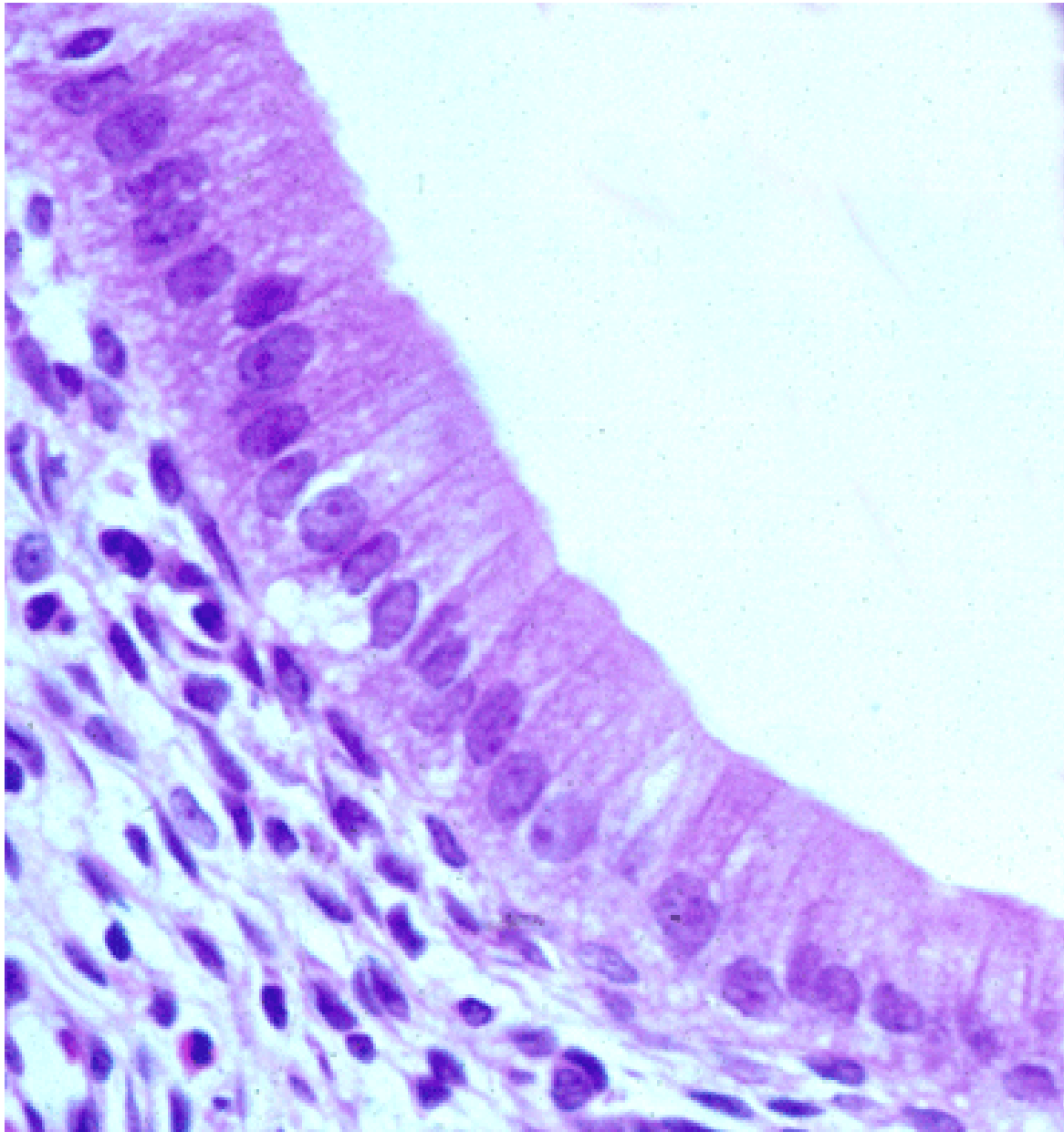
Tejido nervioso



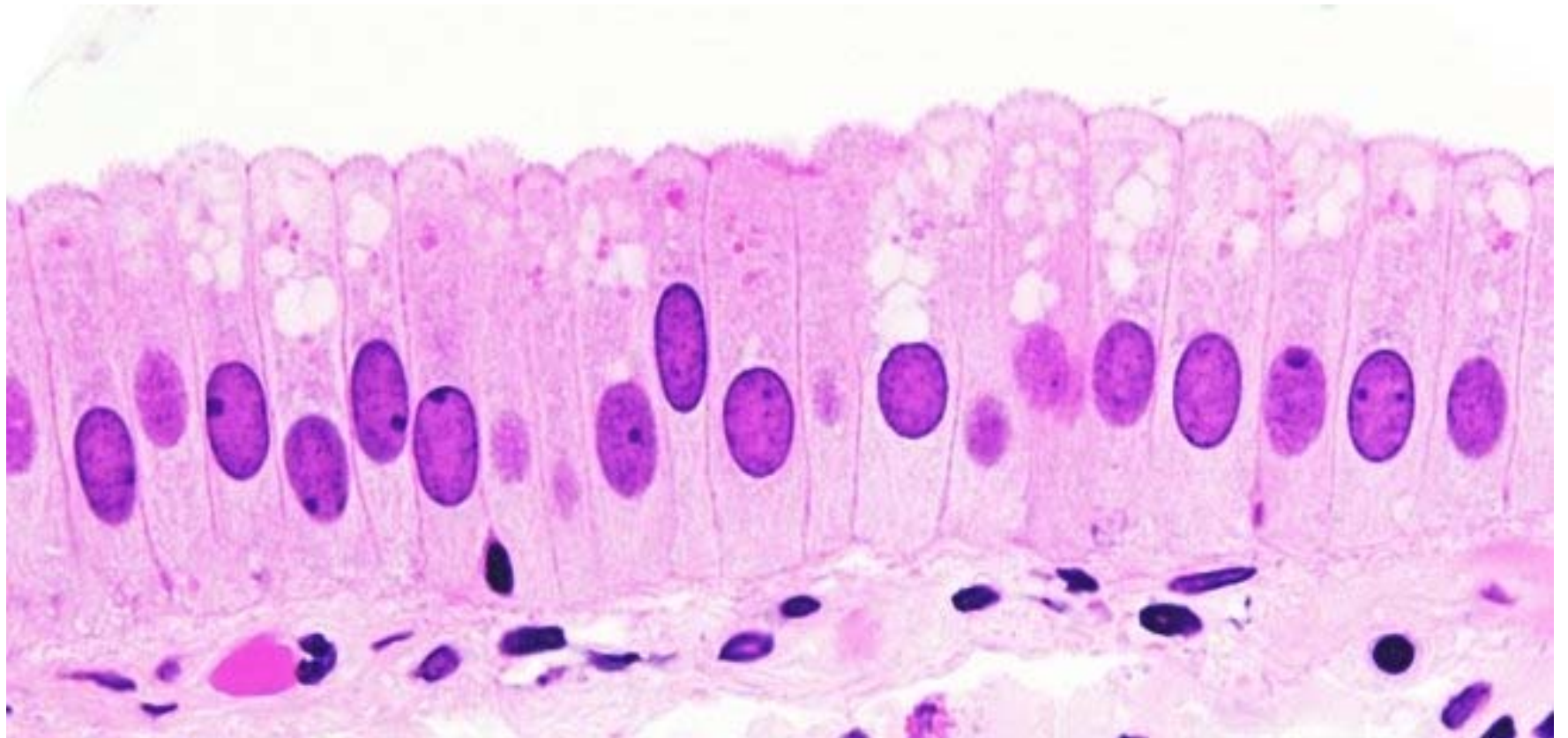


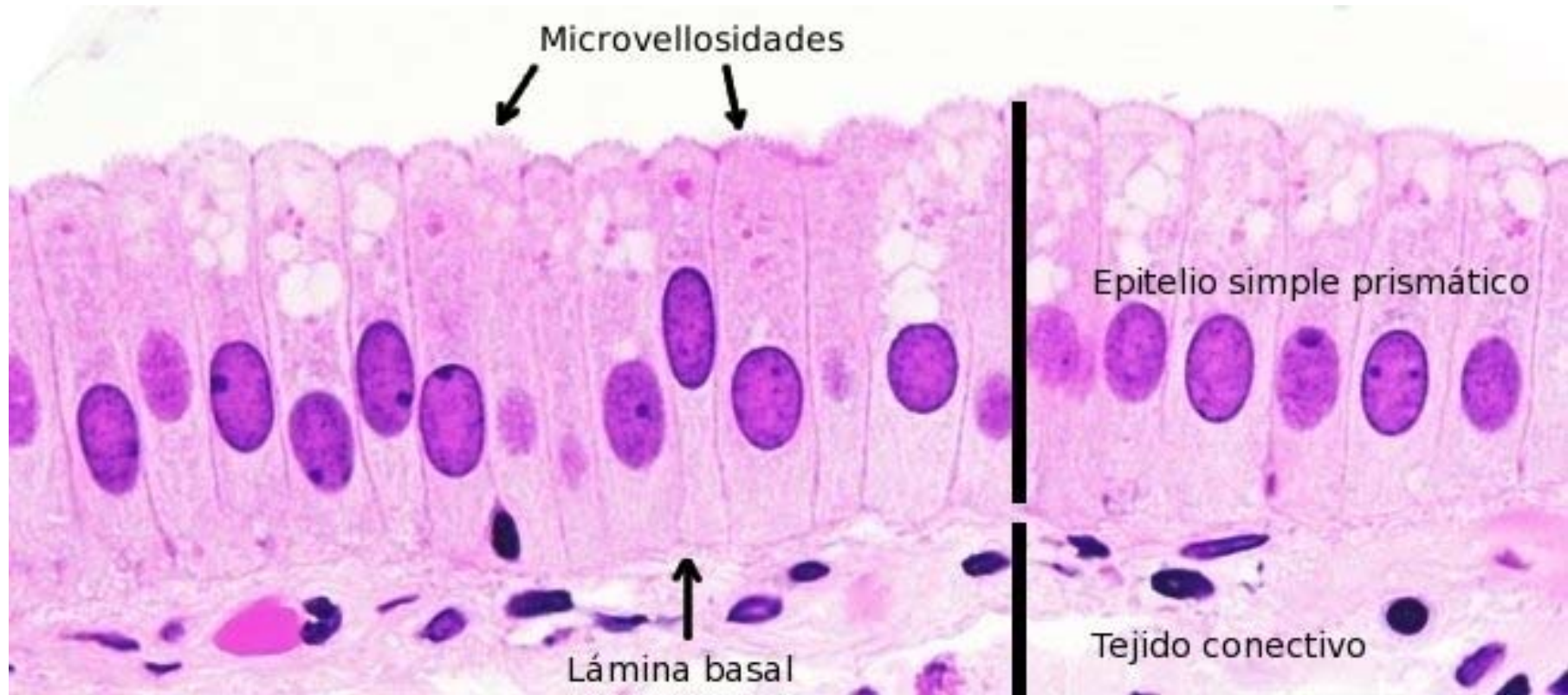
Tejido epitelial simple pavimentoso (*mucosa bucal*)



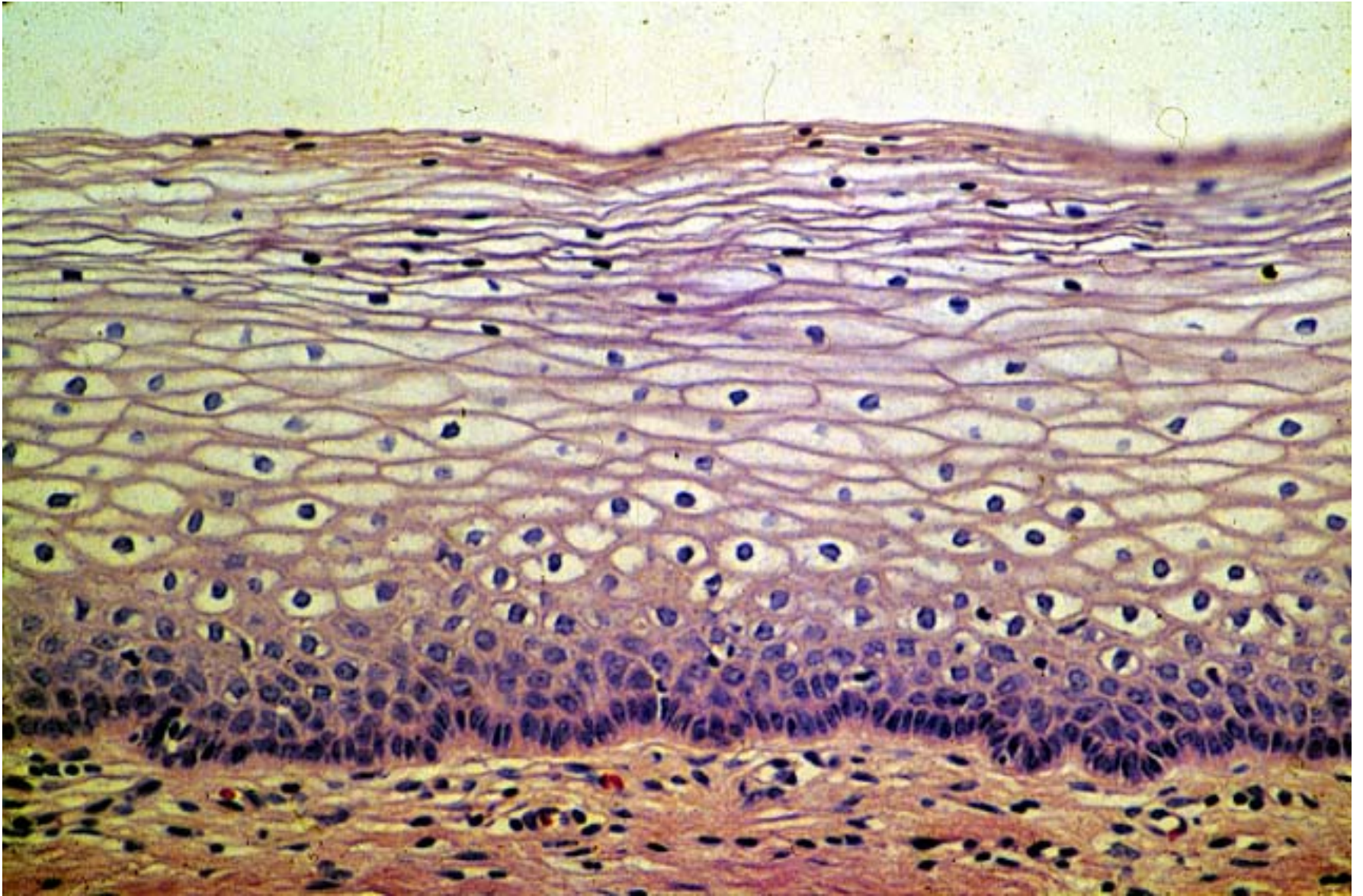


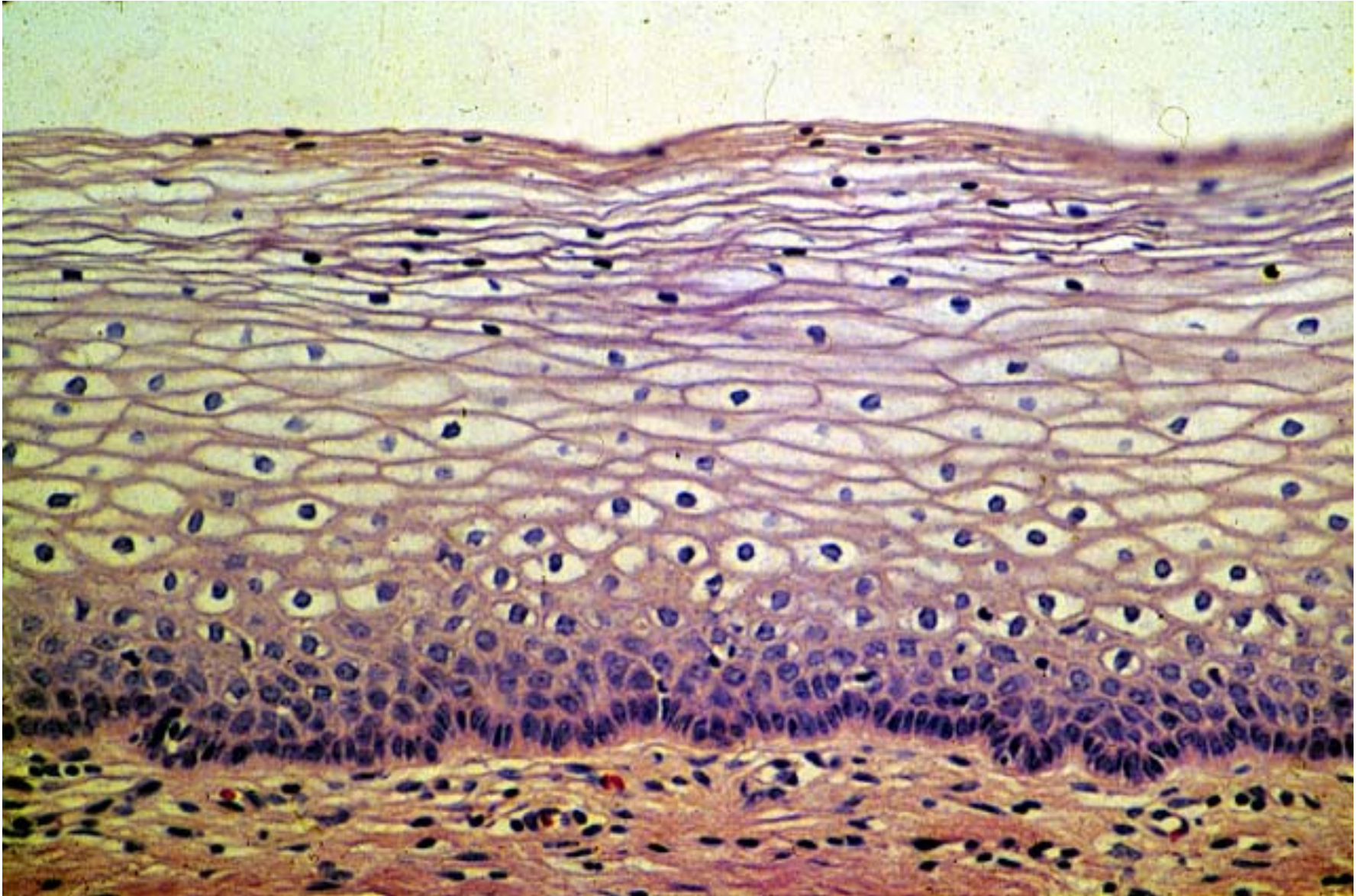
Tejido epitelial simple cúbico



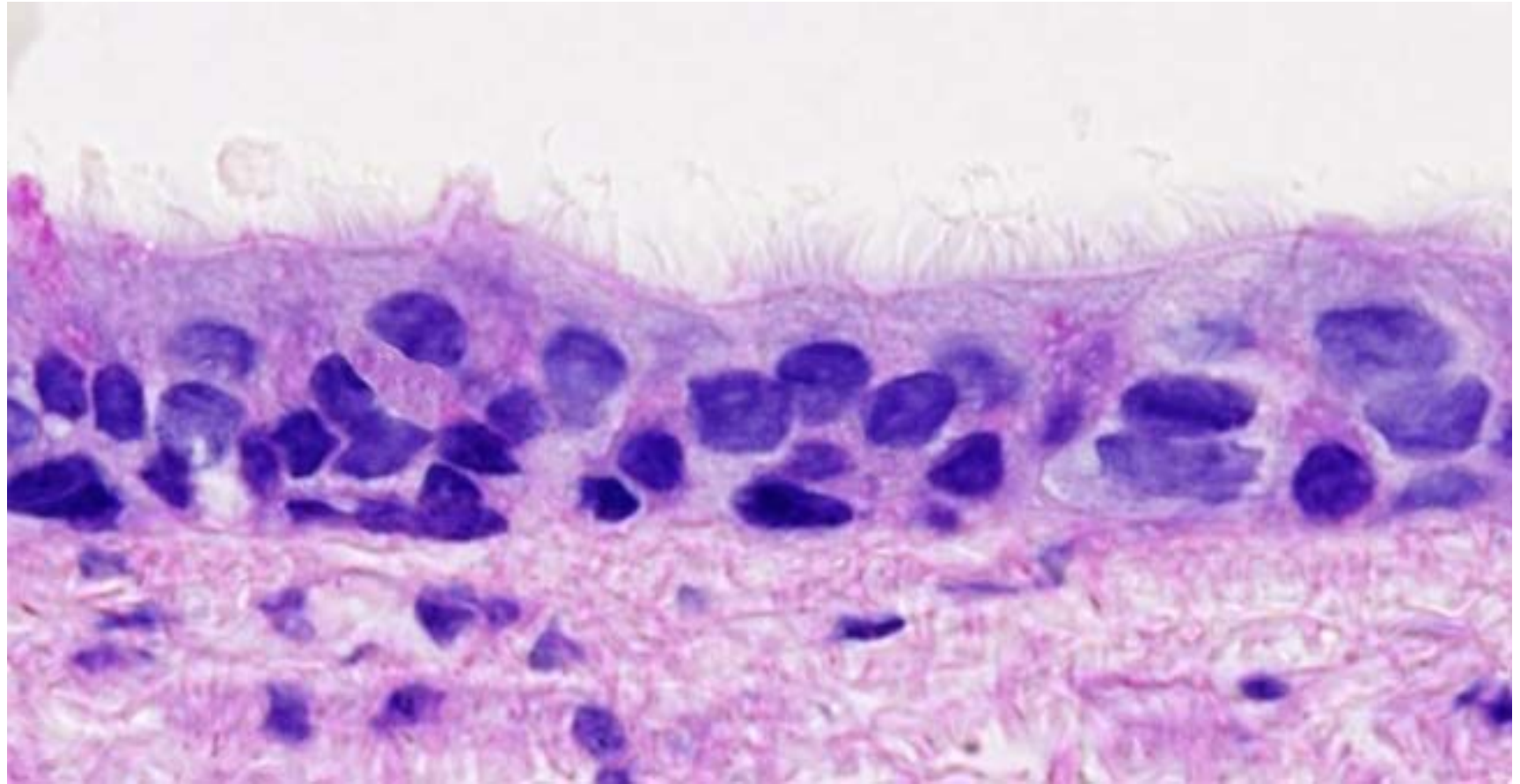


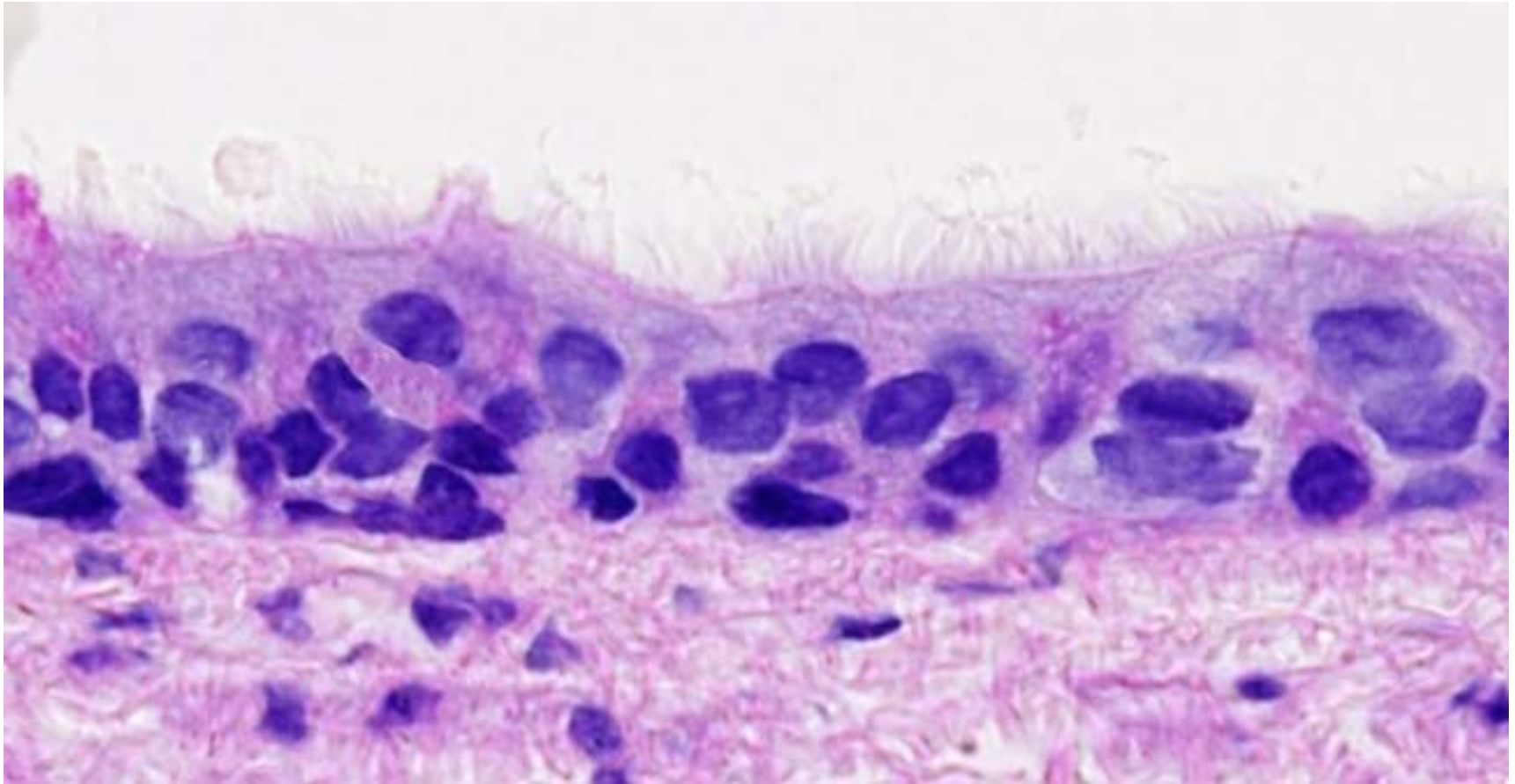
Tejido epitelial simple pismático (vesicula biliar)



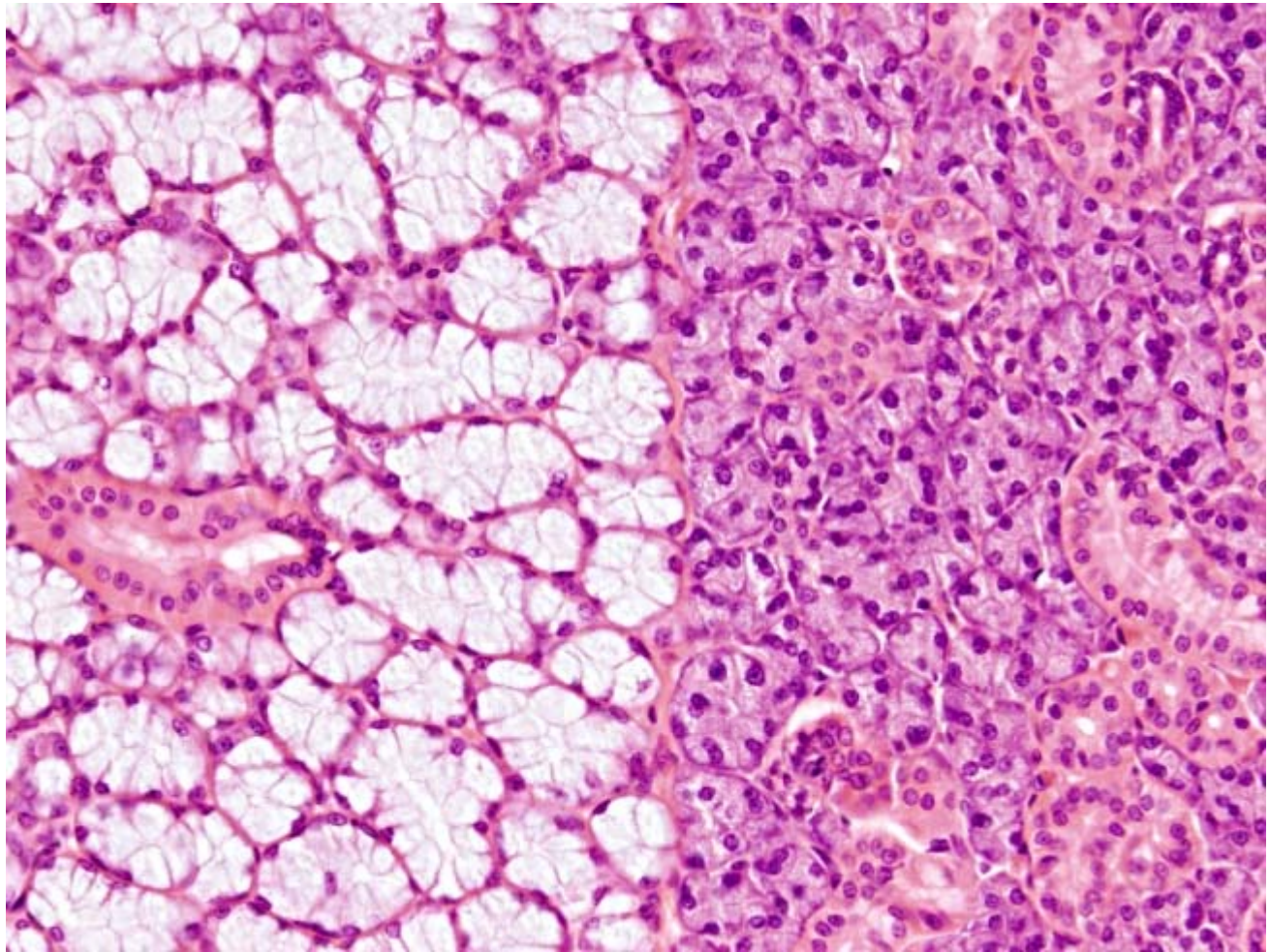


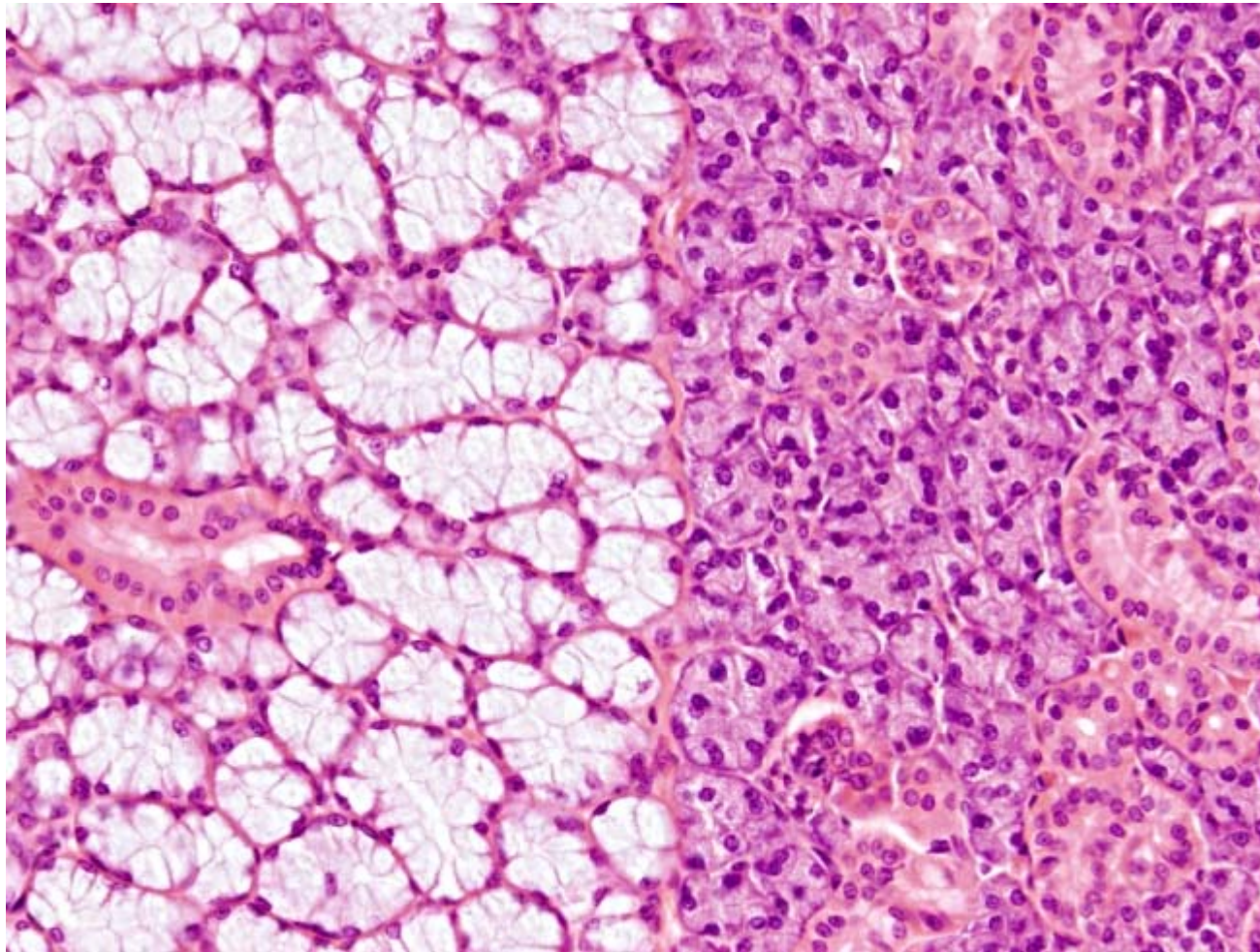
Tejido epitelial pluriestratificado pavimentoso (*porción vaginal*)



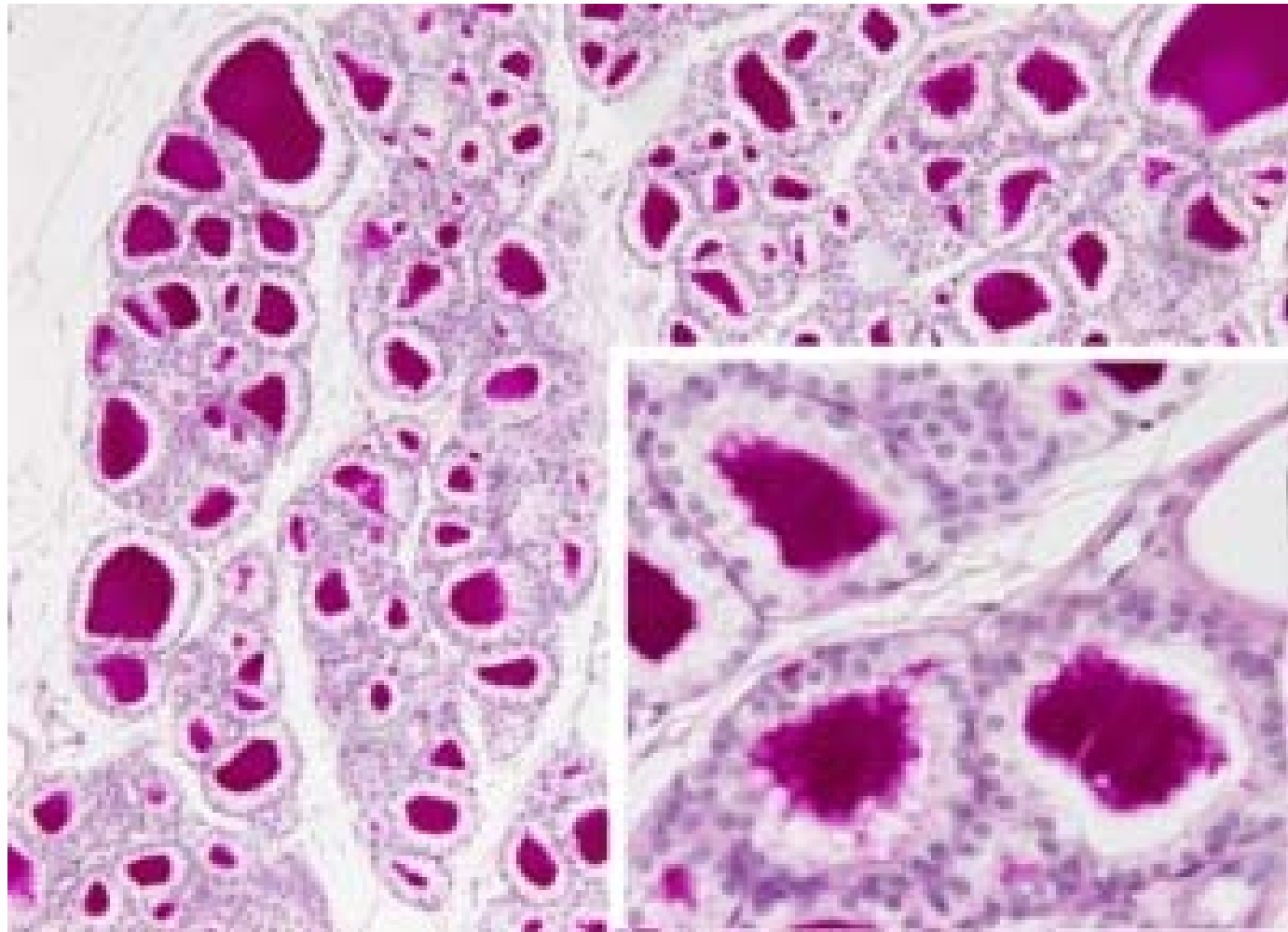


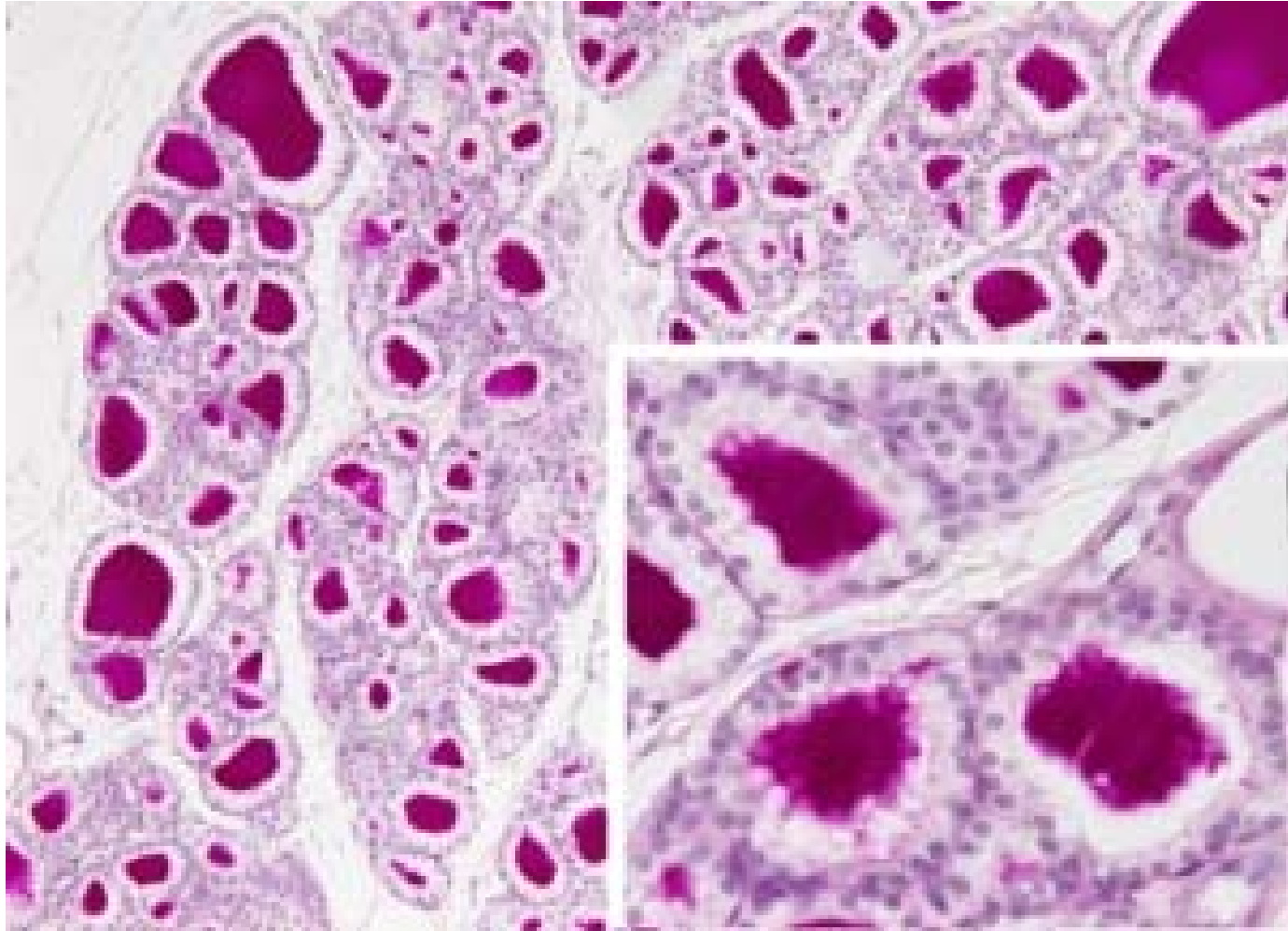
Epitelio pseudoestratificado (tráquea de ratón)



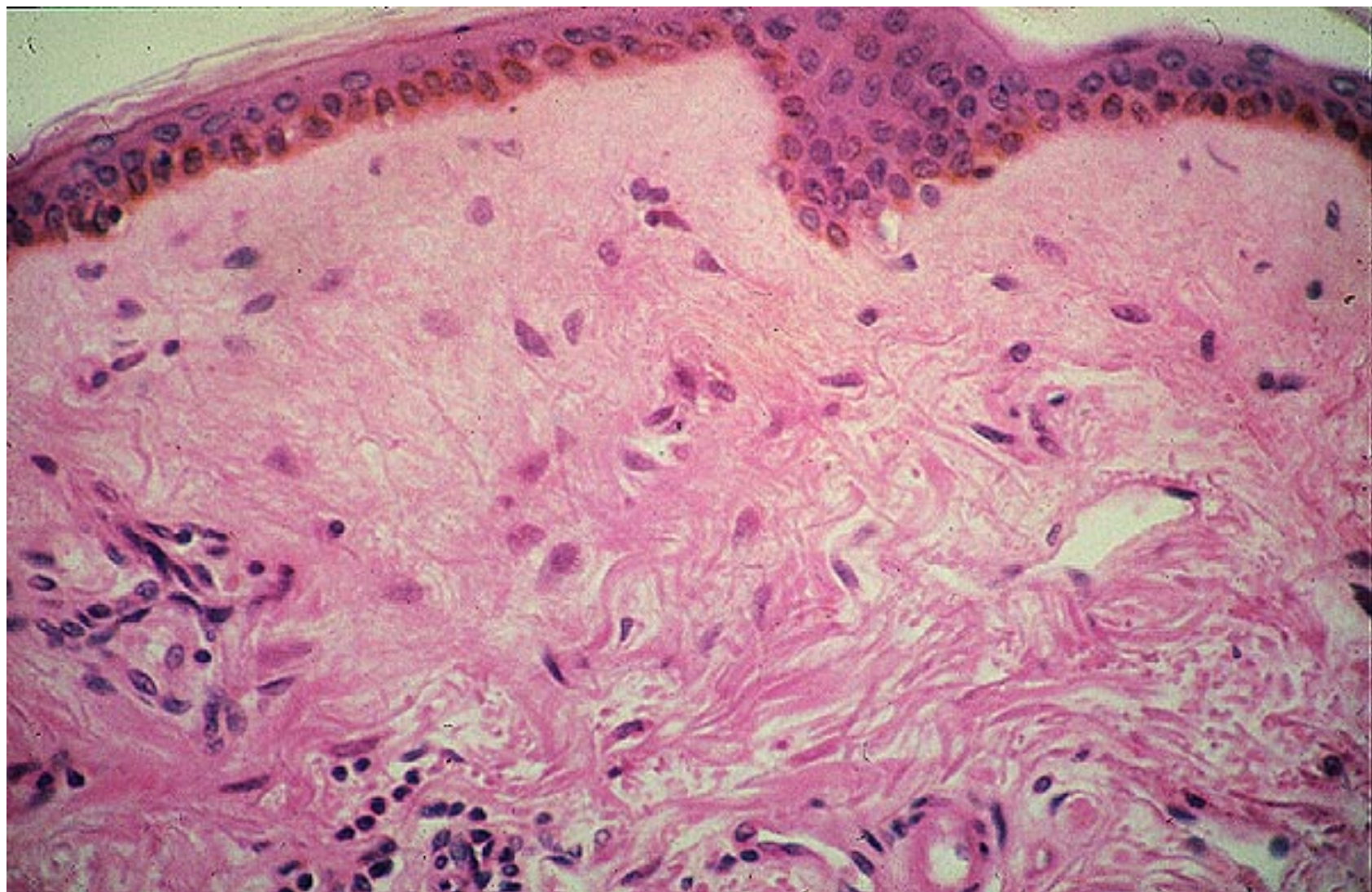


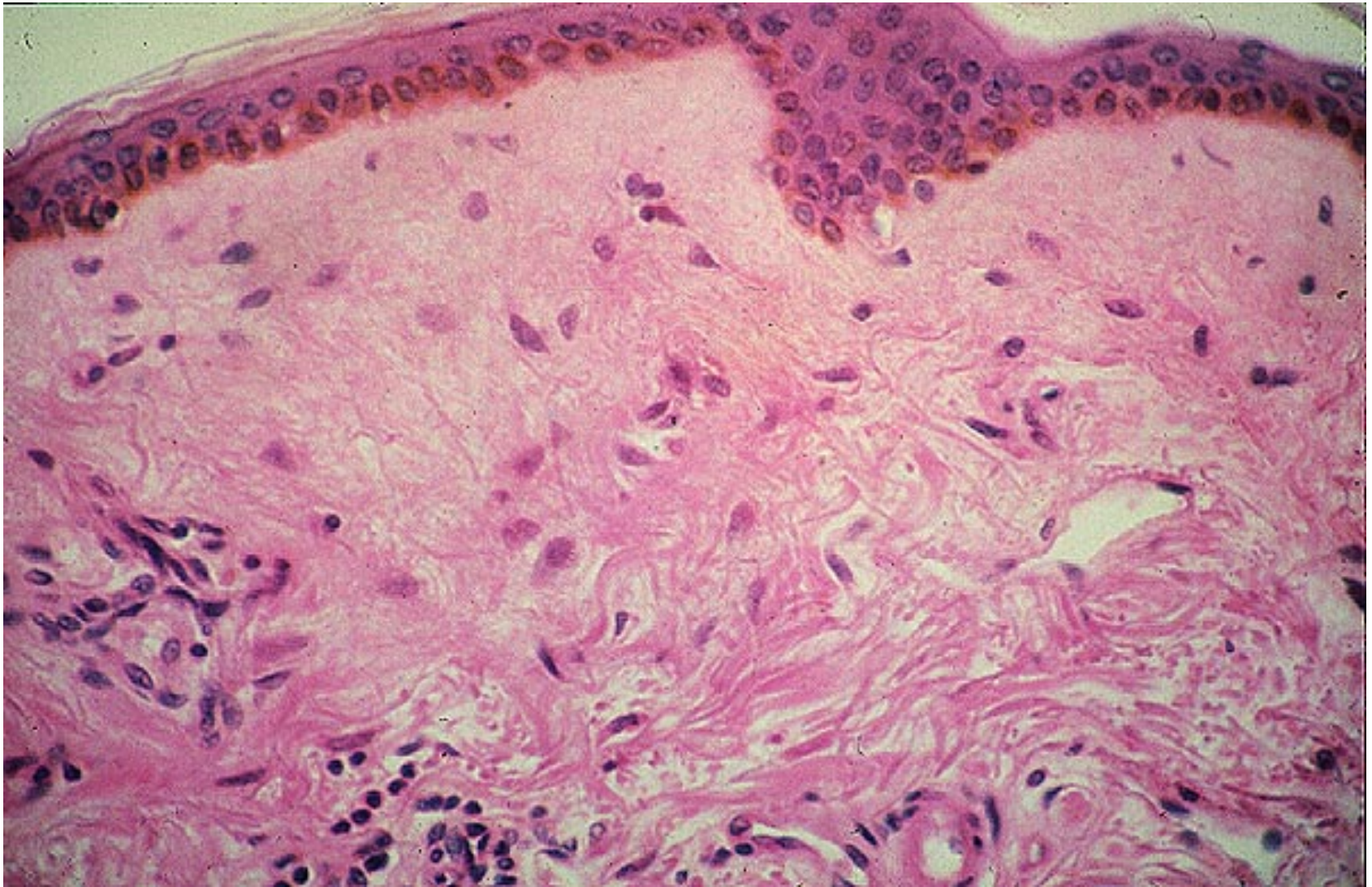
Epitelio glandular (*glándula salival exocrina de ratón*)



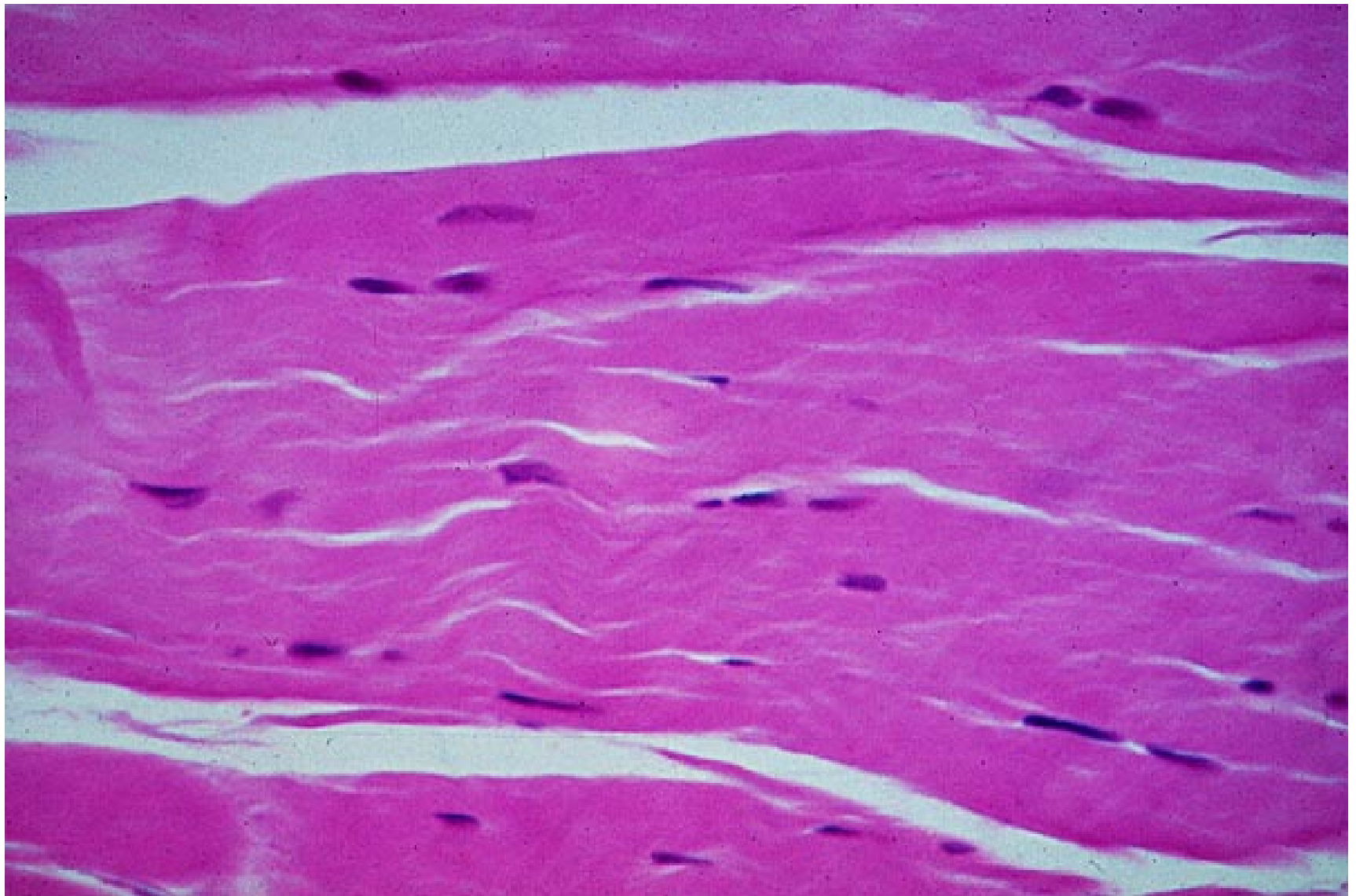


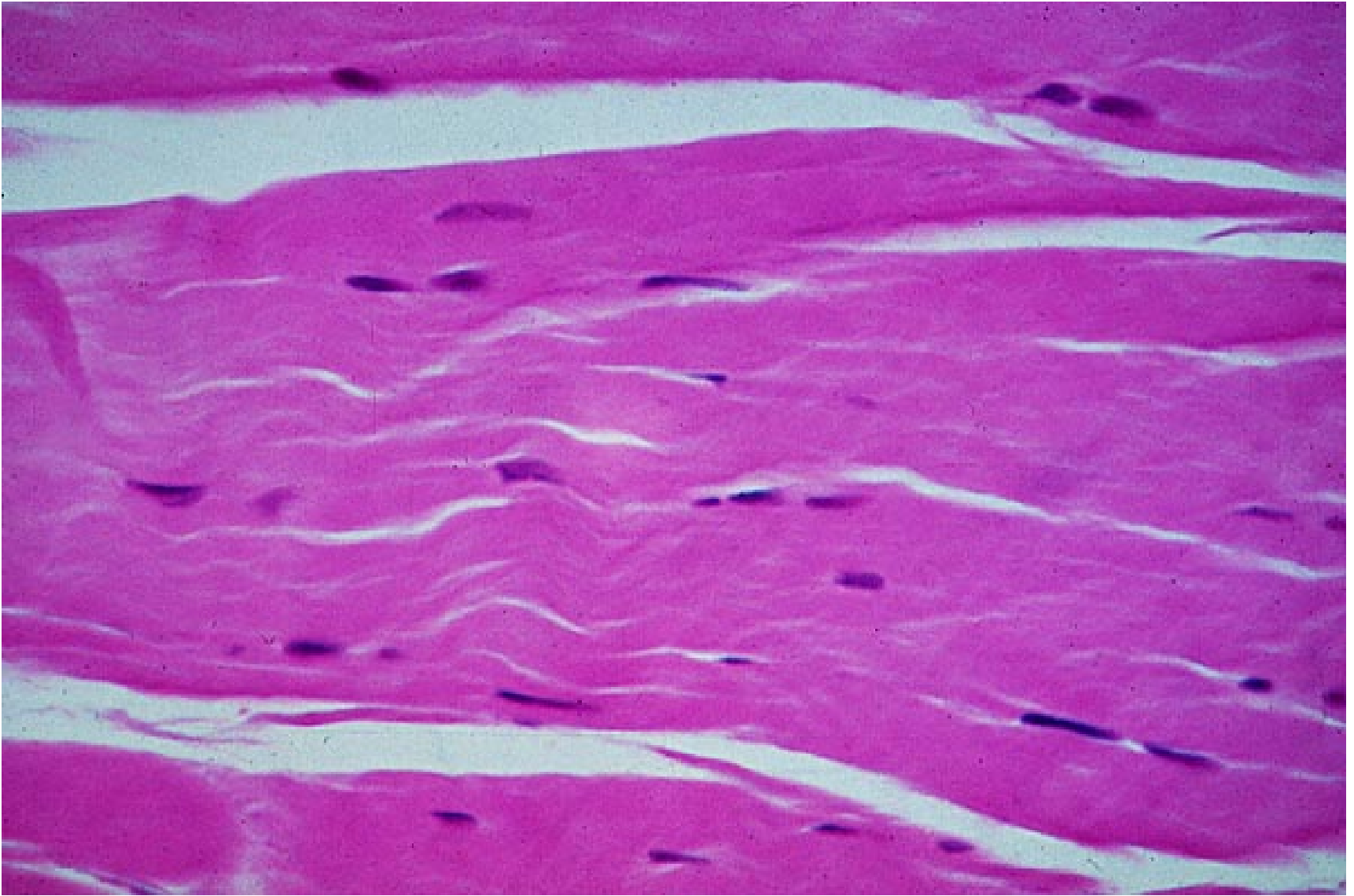
Epitelio glandular (*glándula endocrina, tiroides de ratón*)



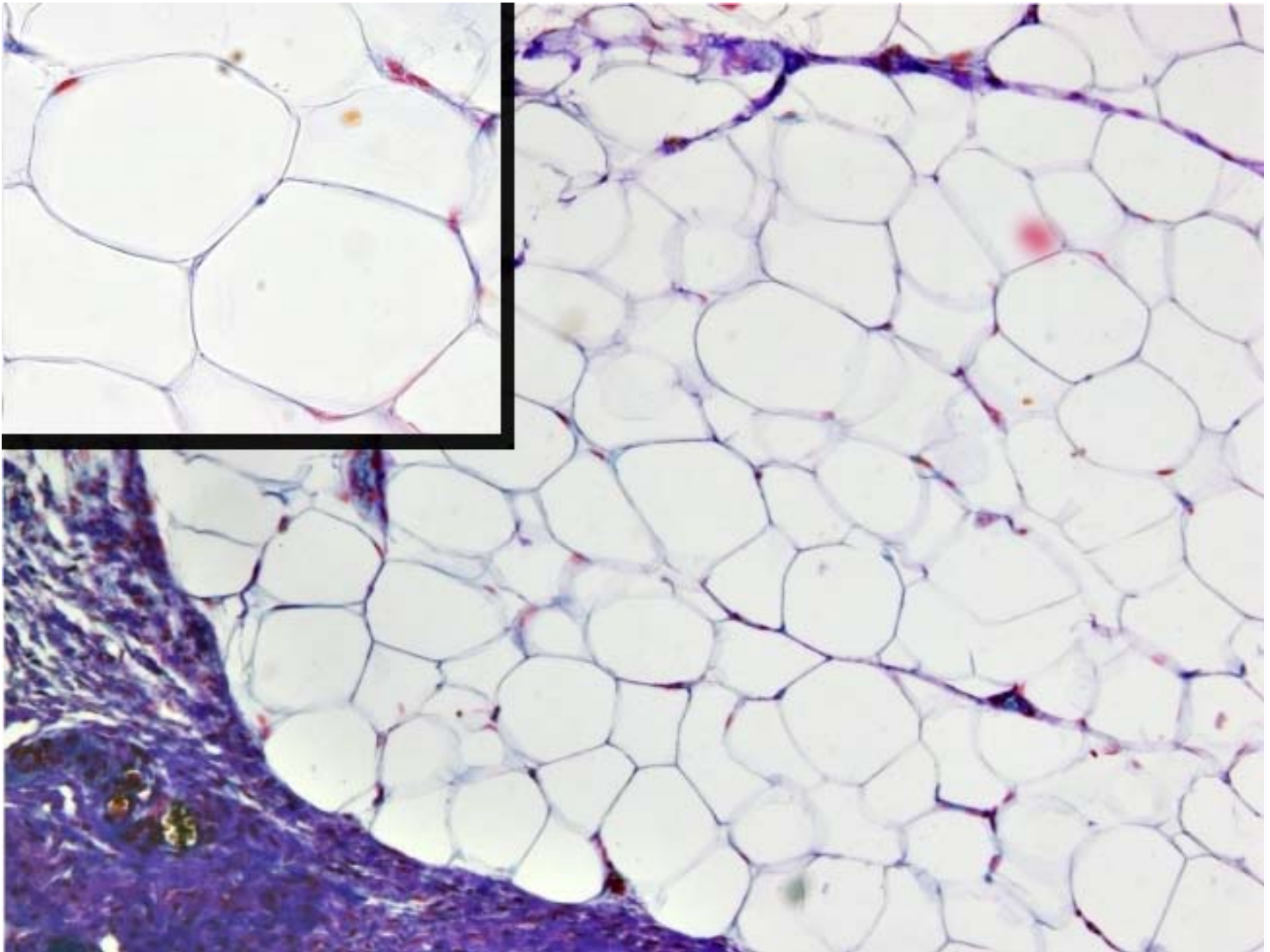


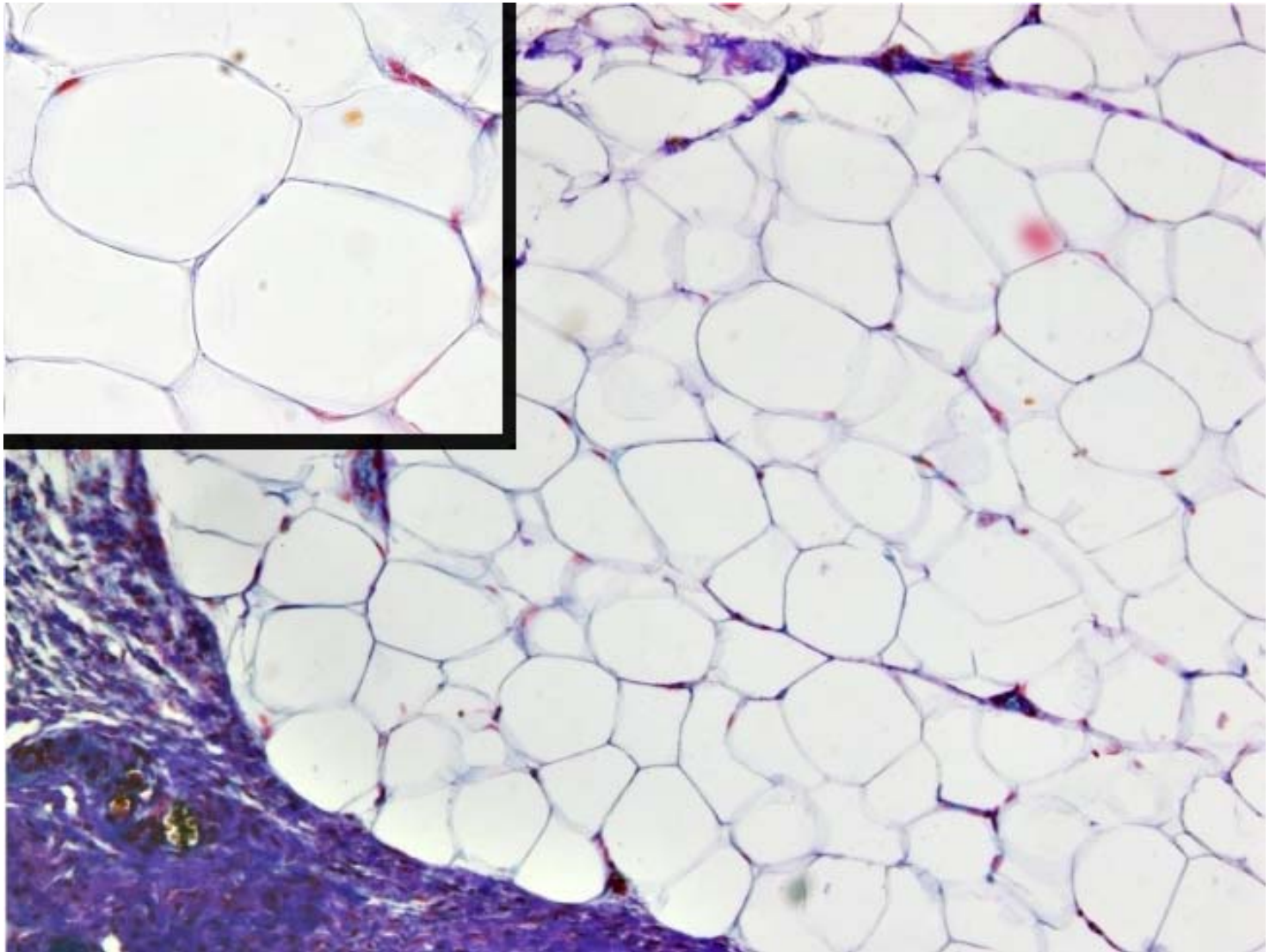
Tejido conjuntivo laxo (dermis)



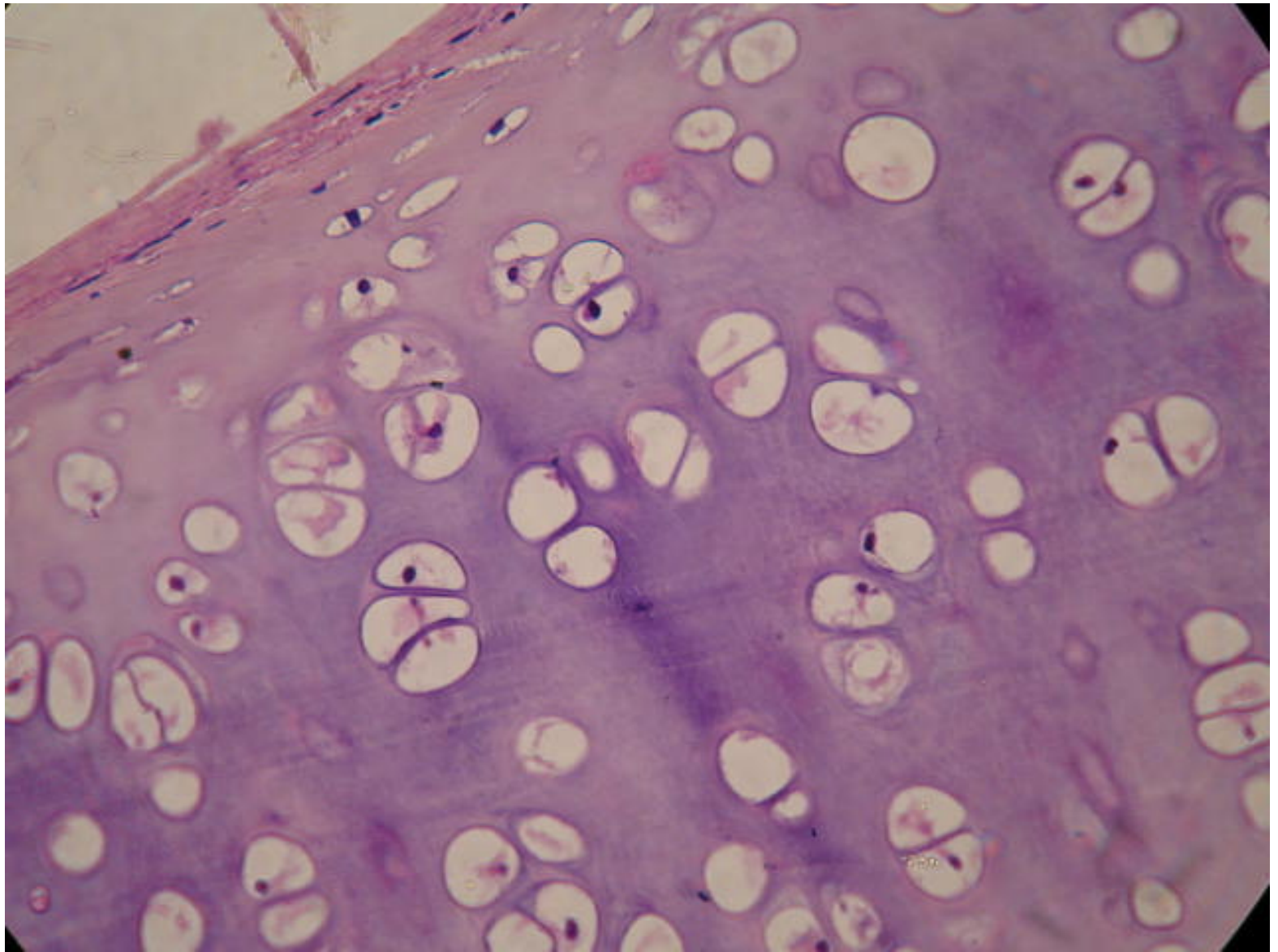


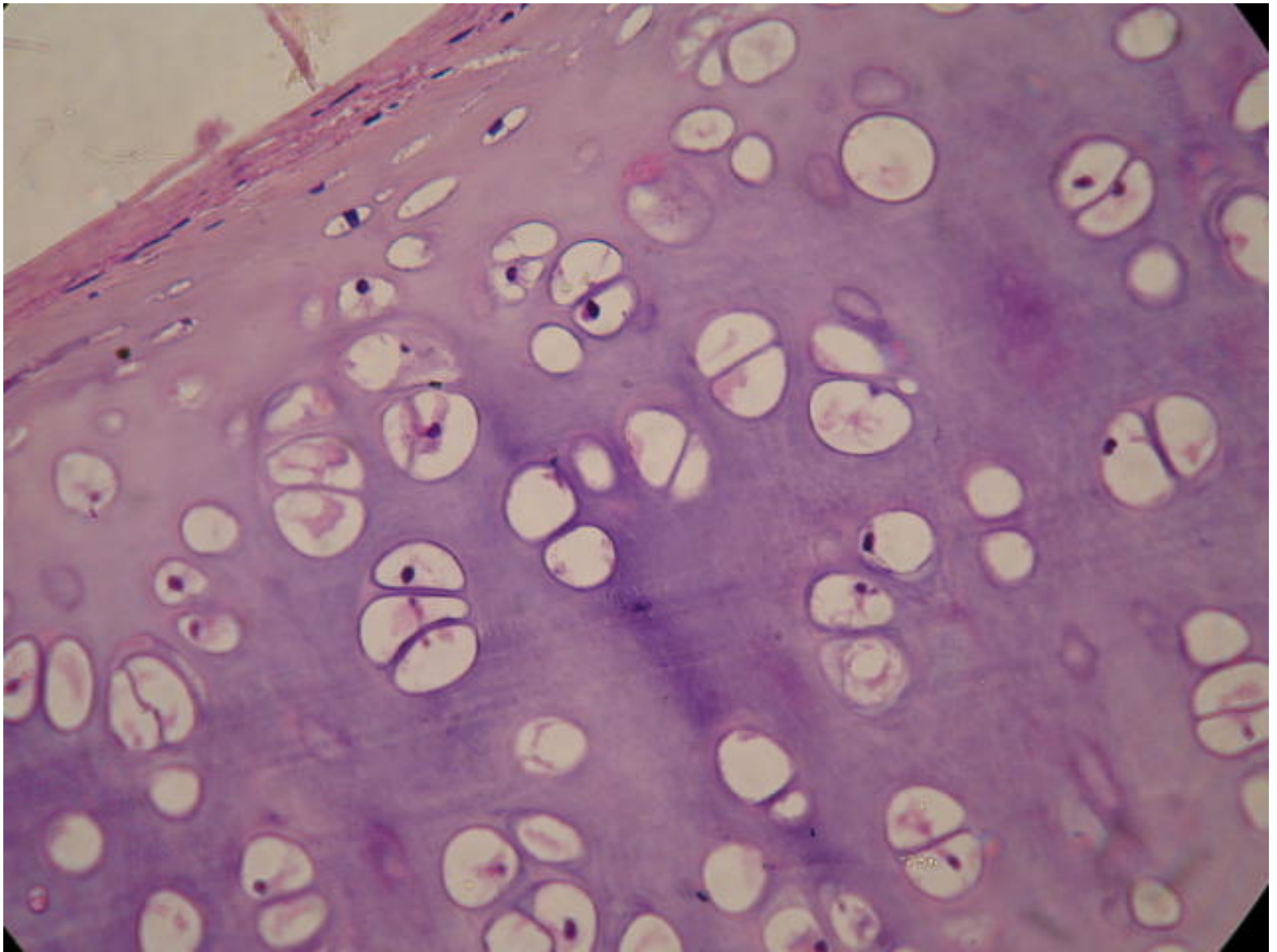
Tejido conjuntivo fibroso (tendón)



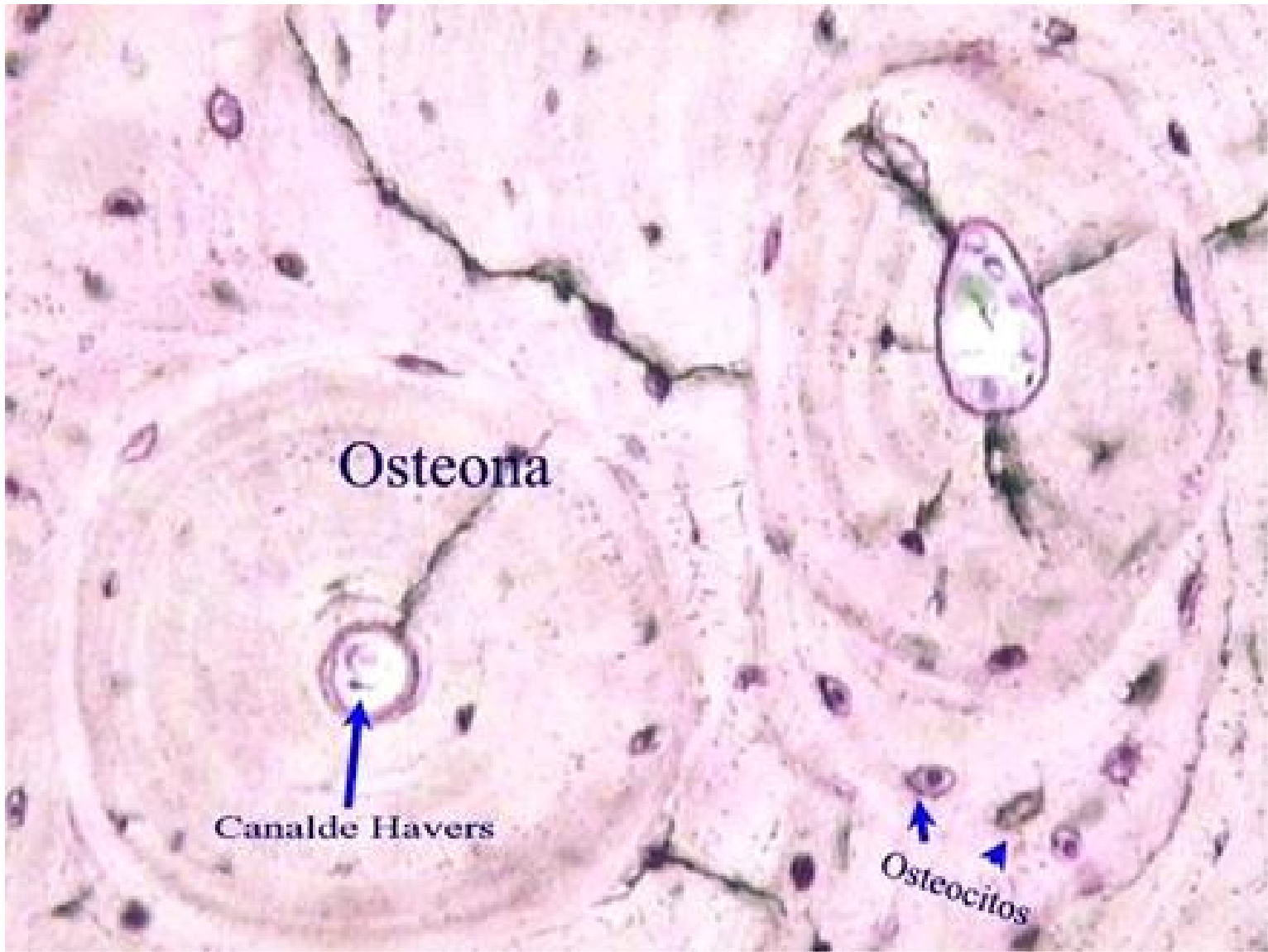


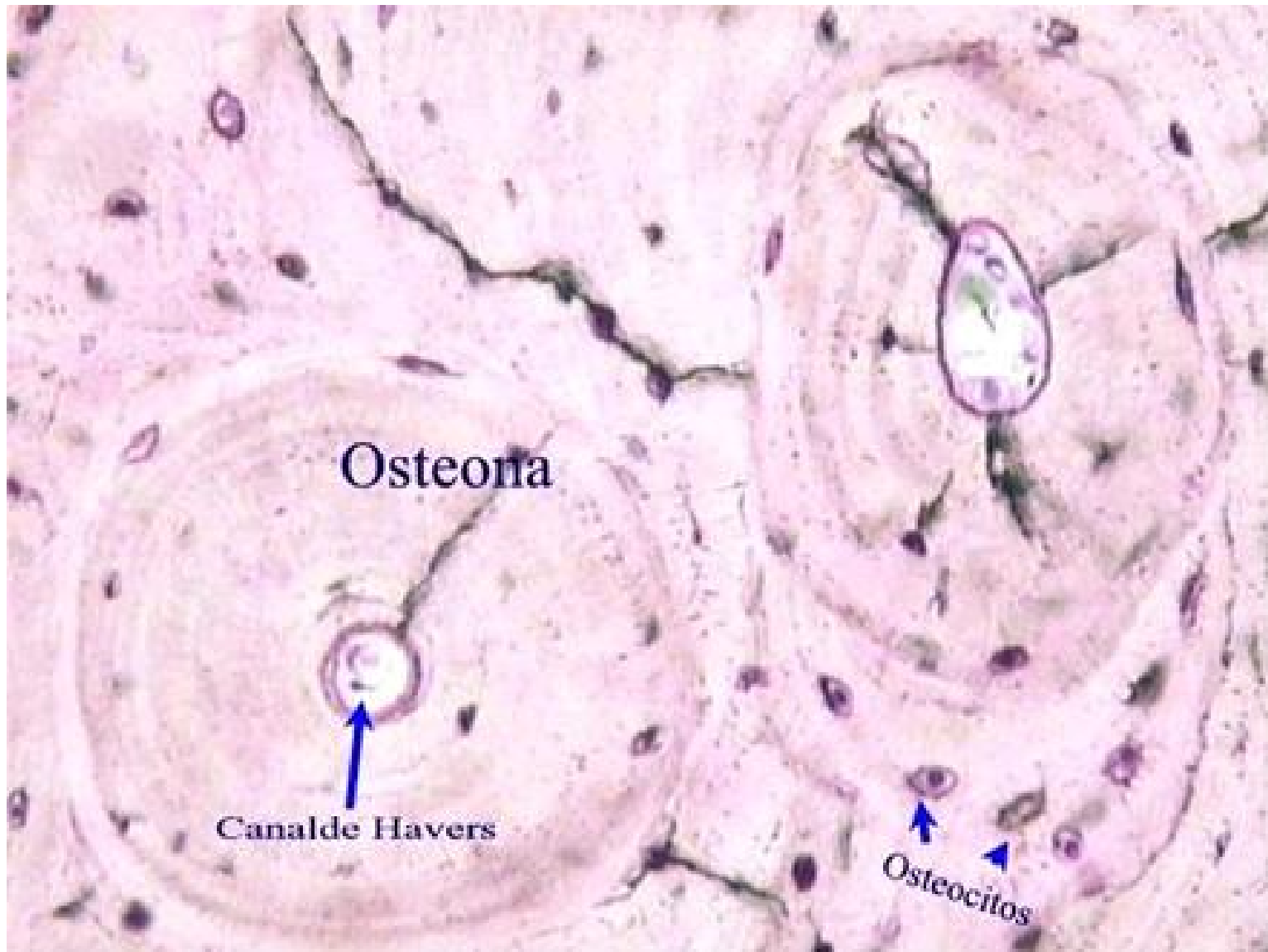
Tejido adiposo (de ratón)



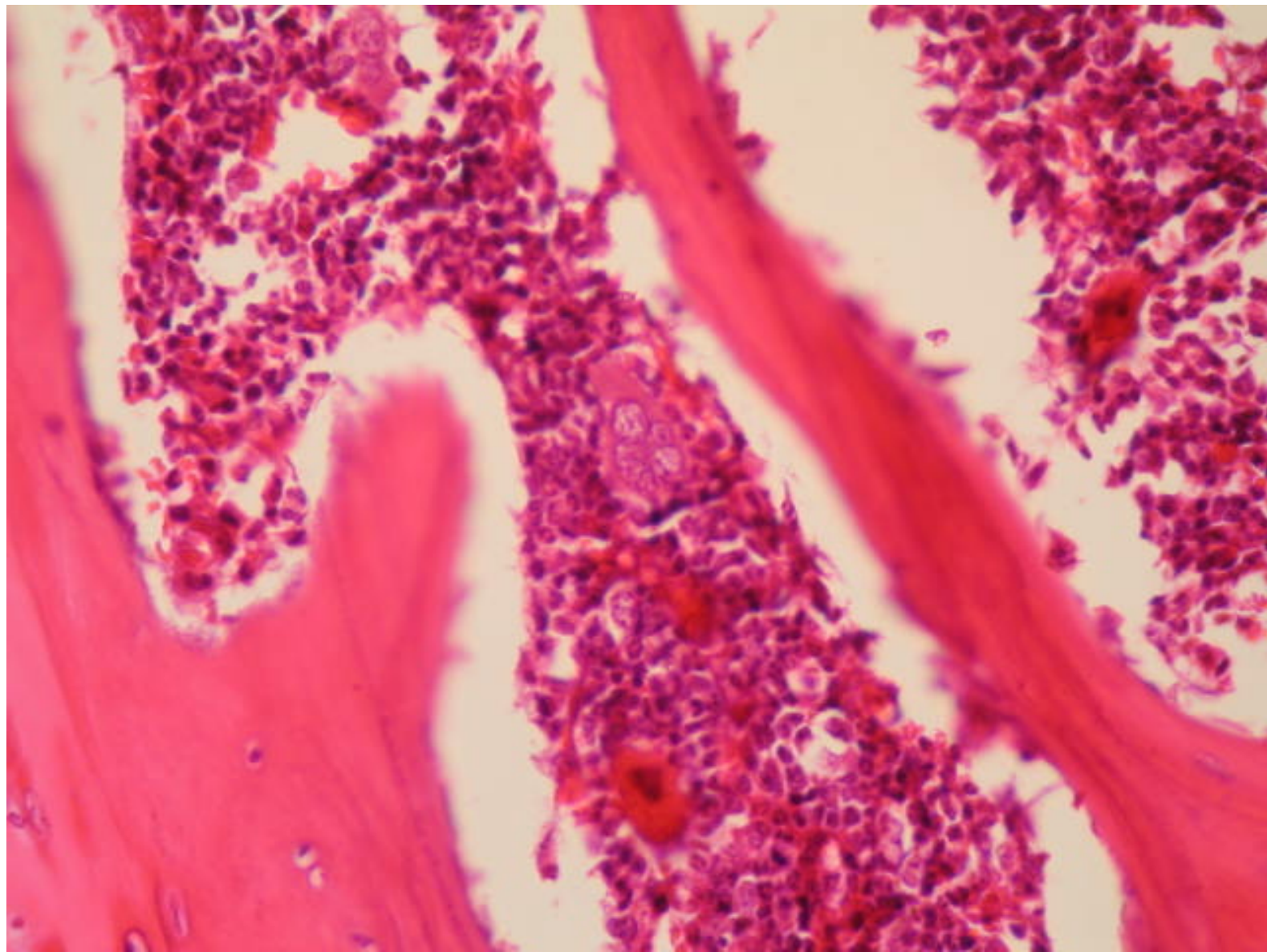


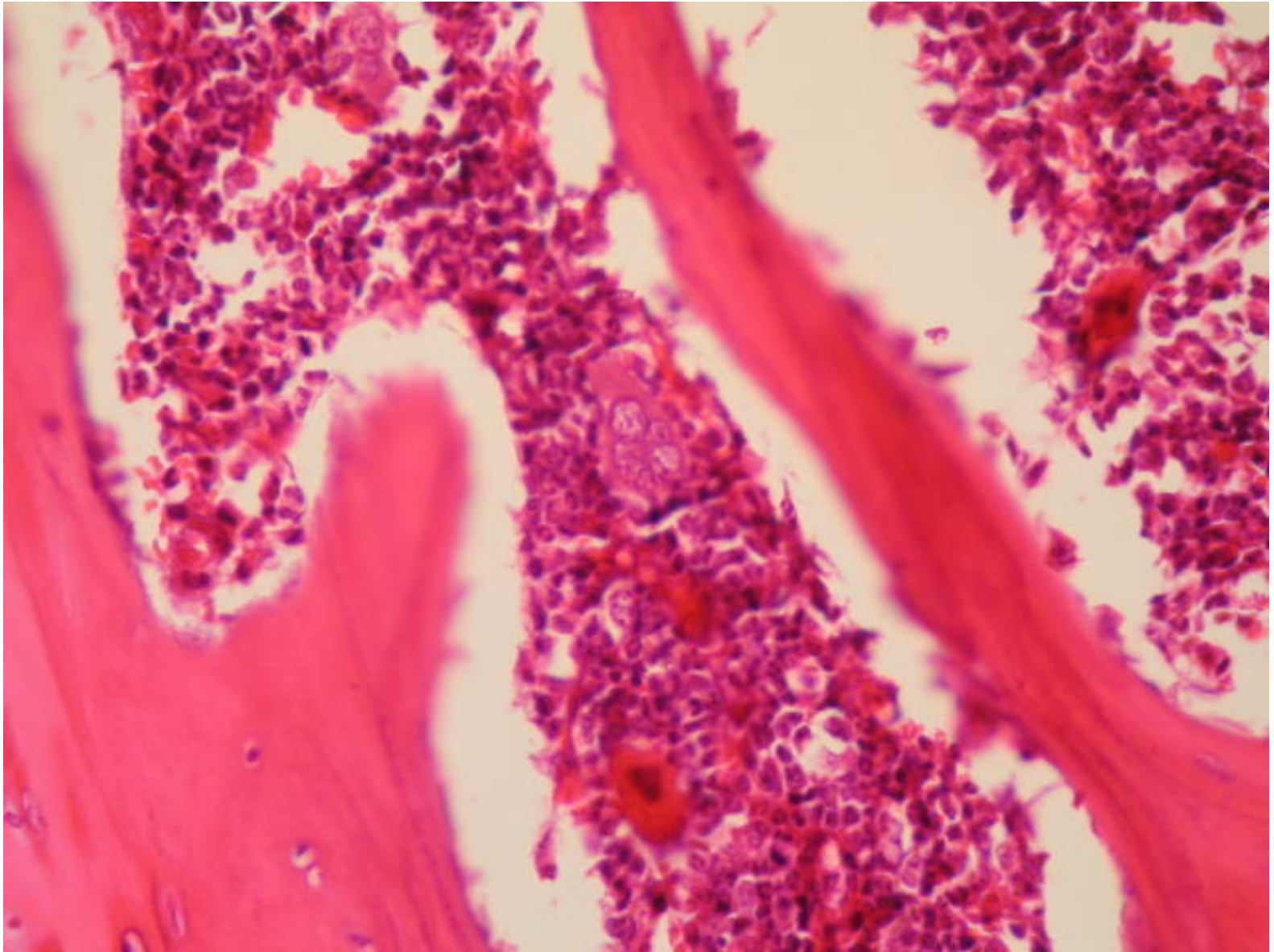
Tejido cartilaginoso (tráquea)



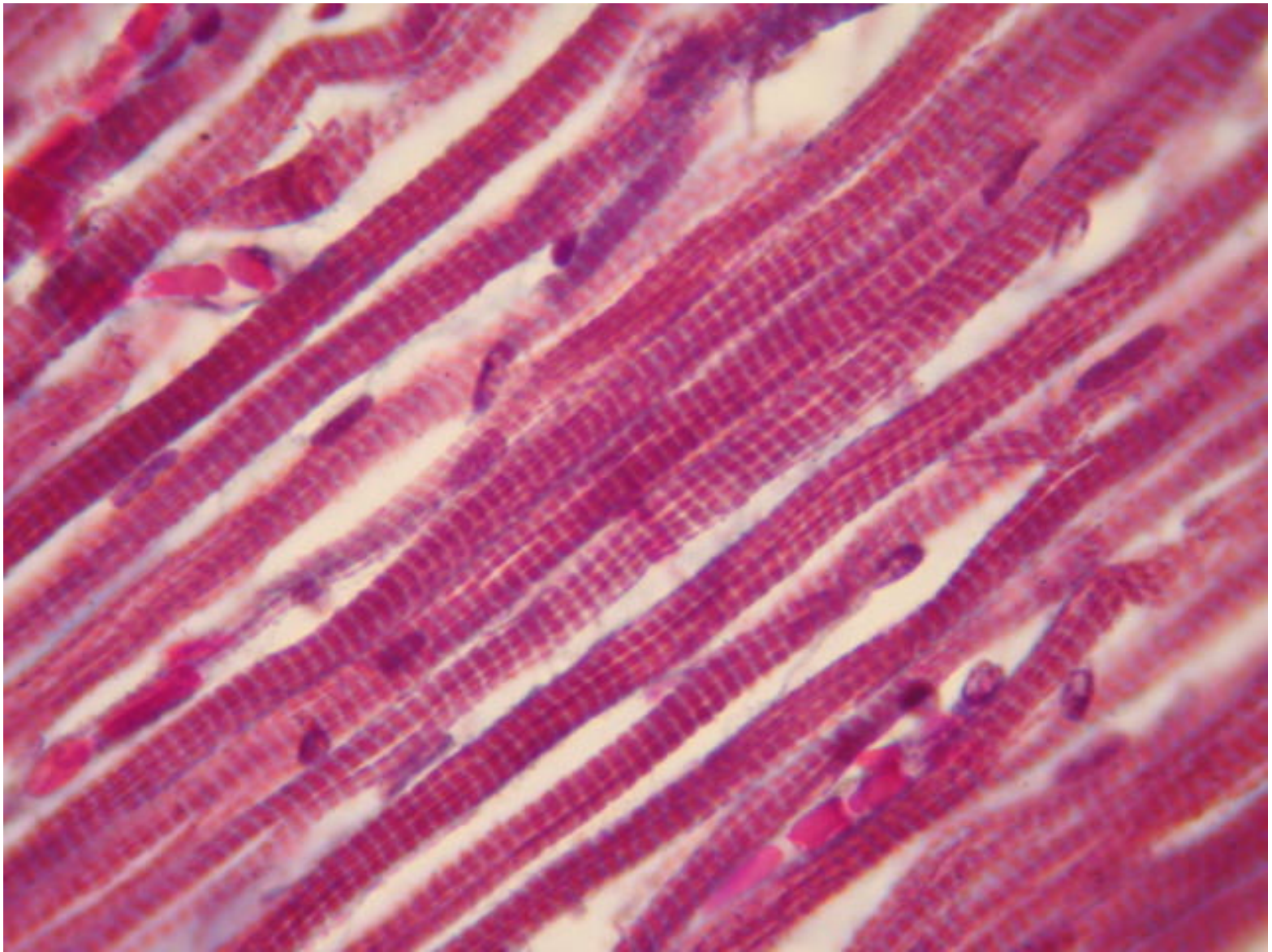


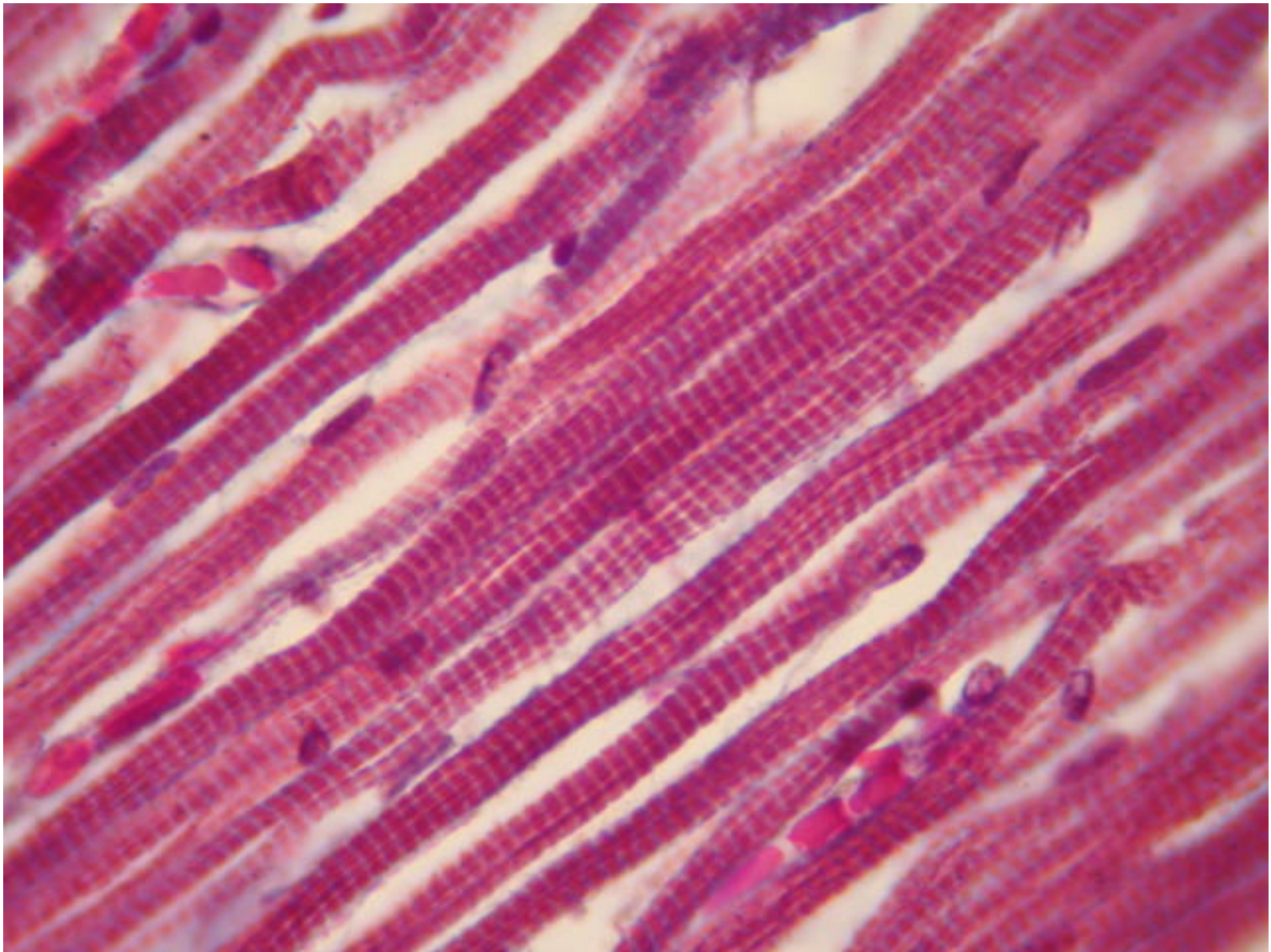
Tejido óseo compacto



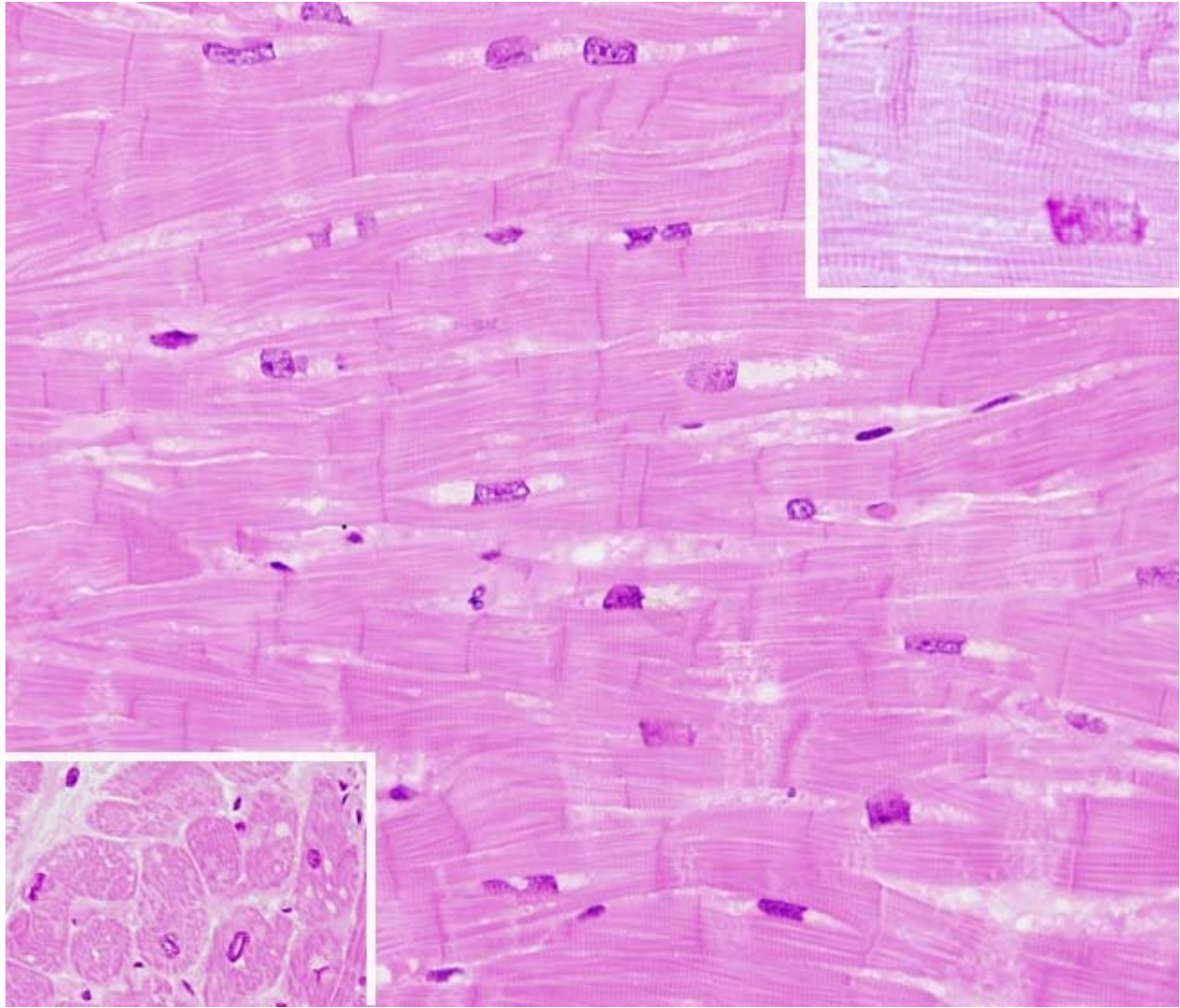


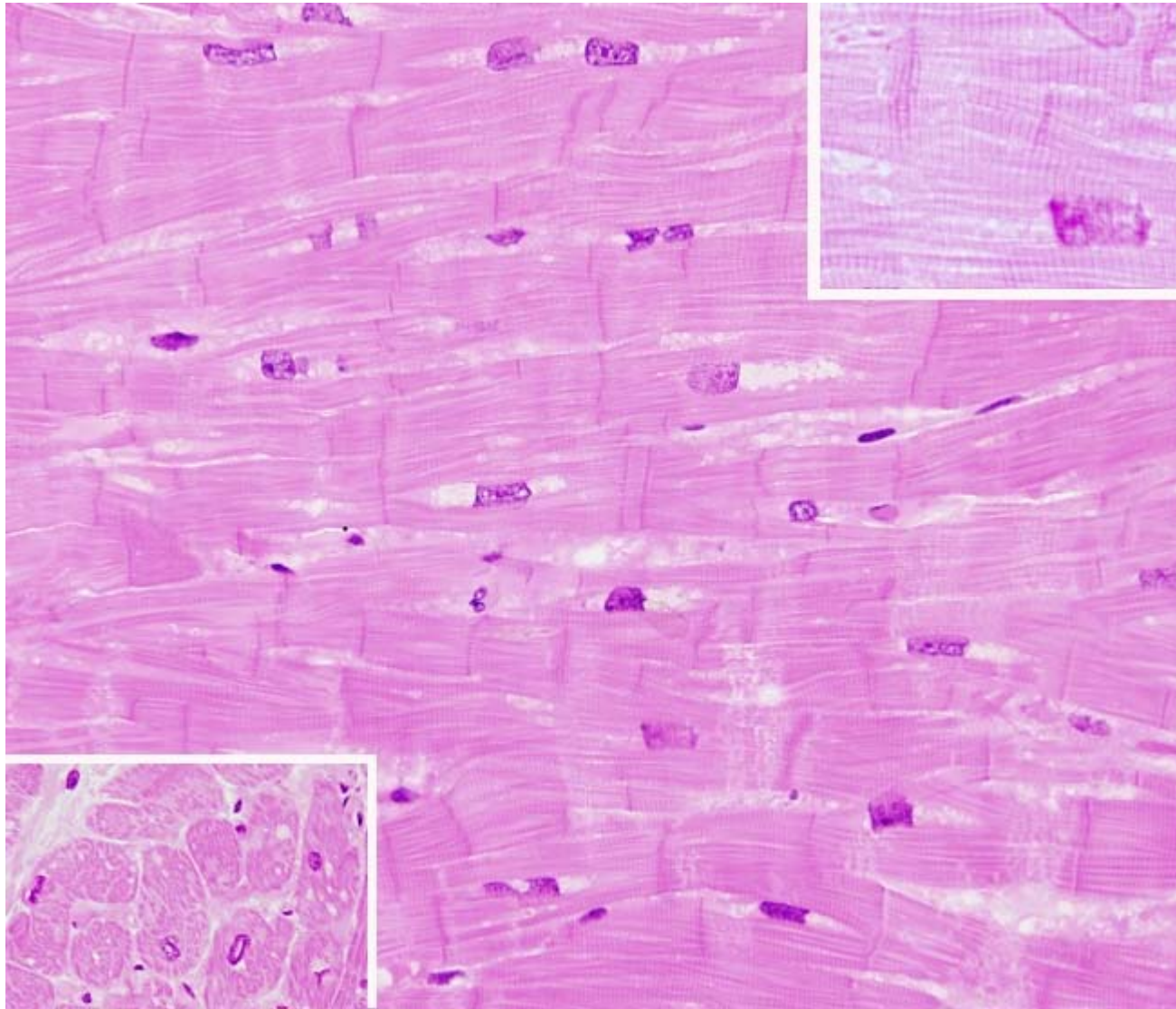
Tejido óseo esponjoso



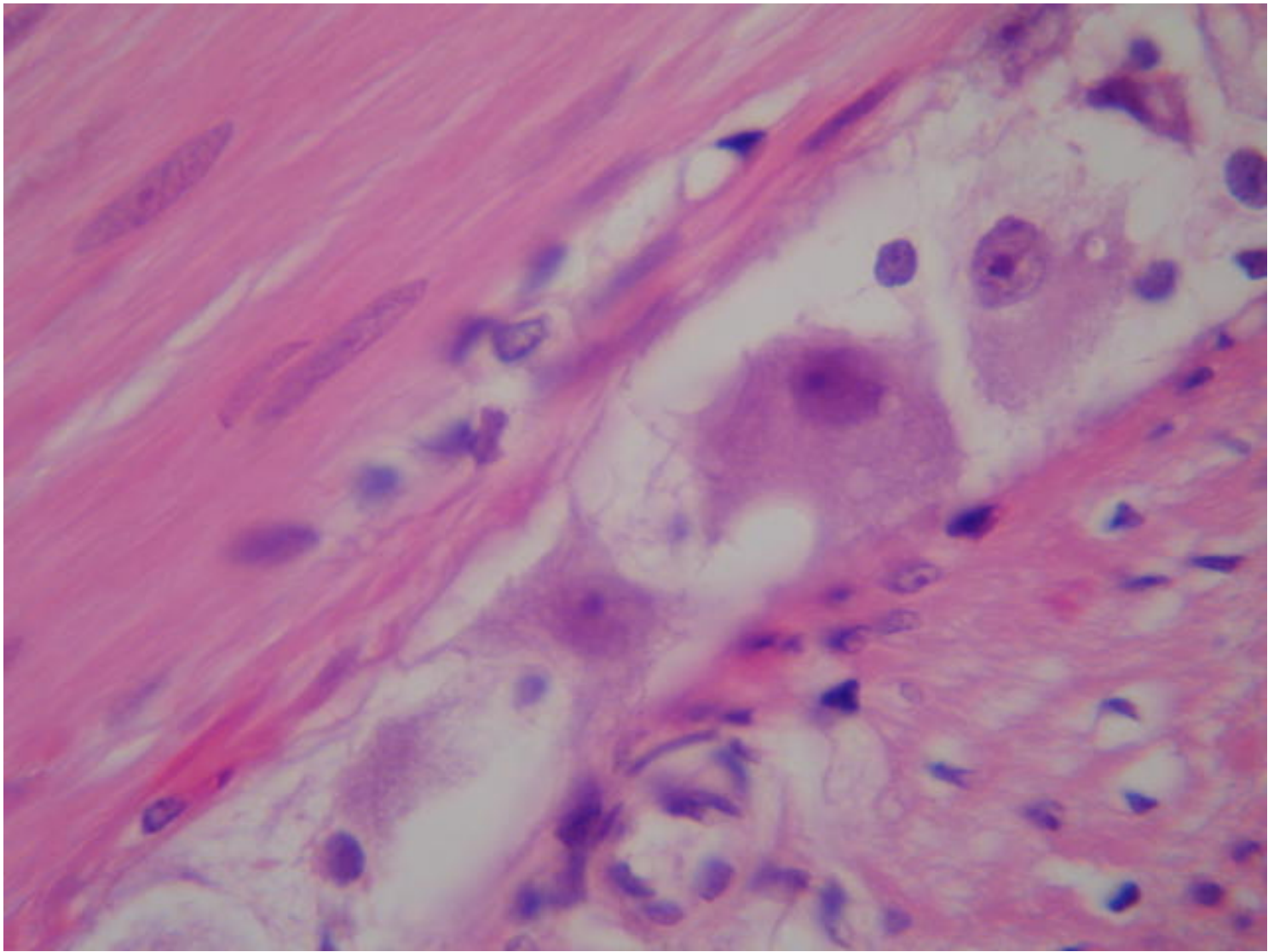


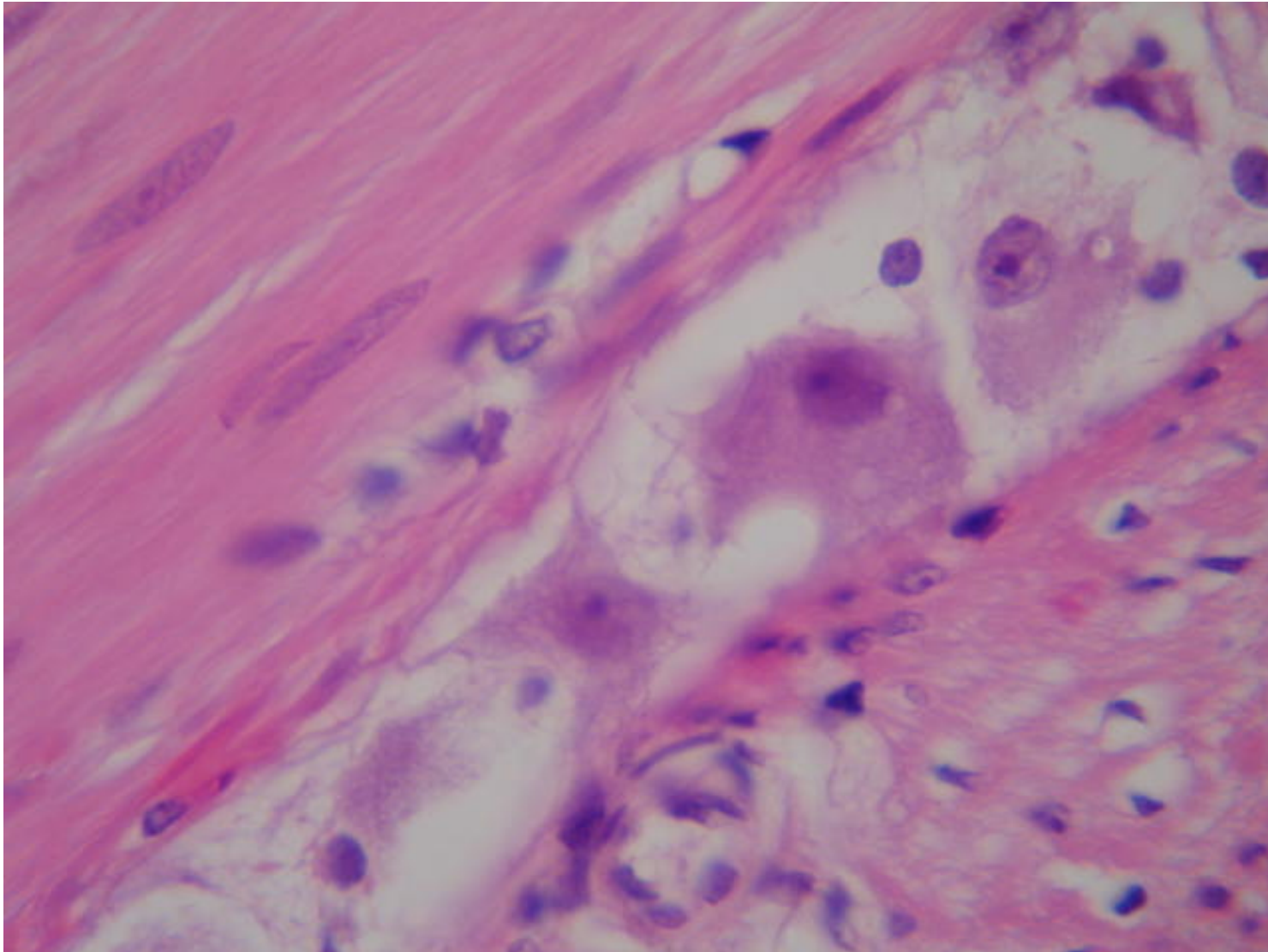
Tejido muscular estriado esquelético



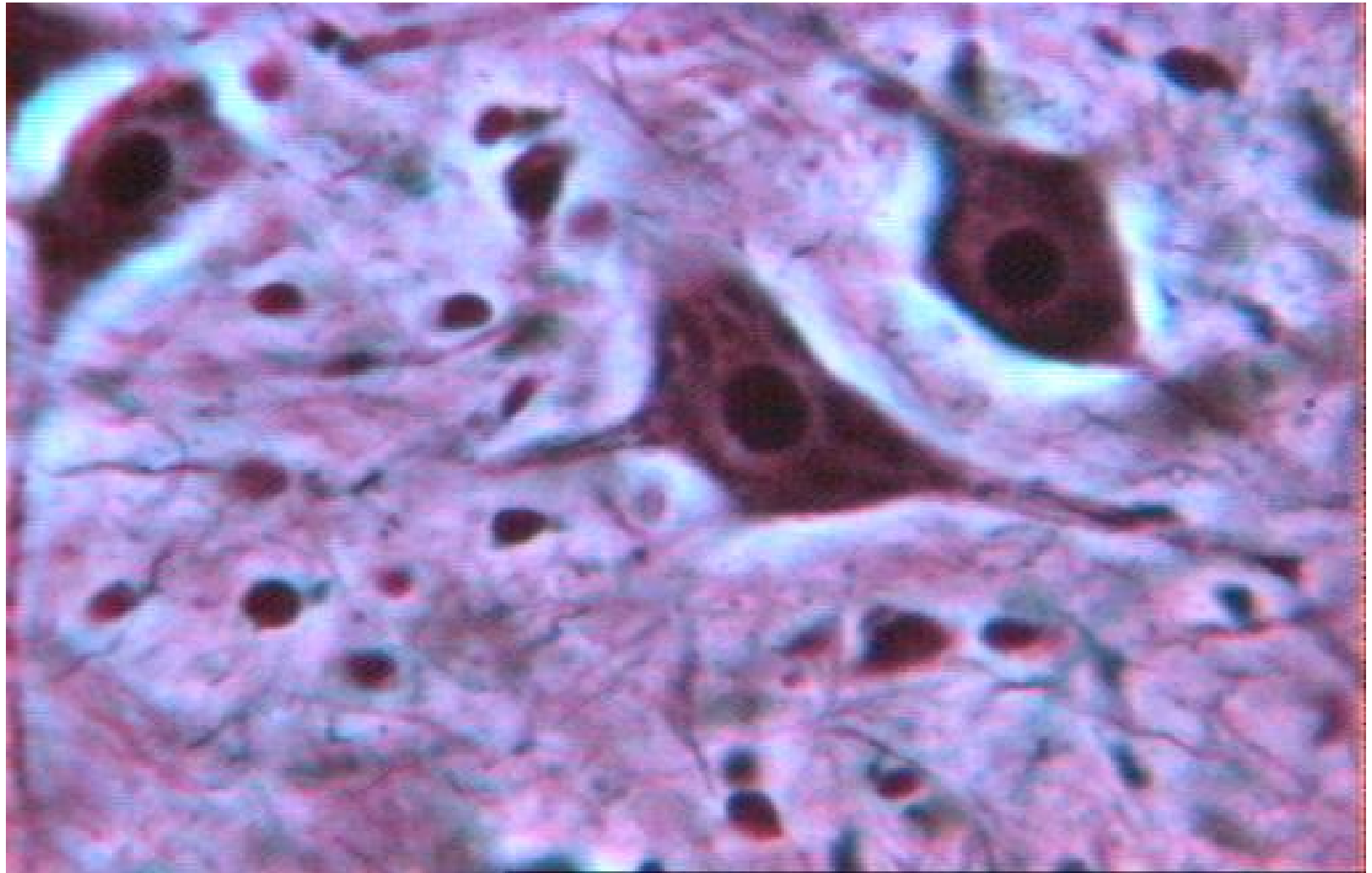


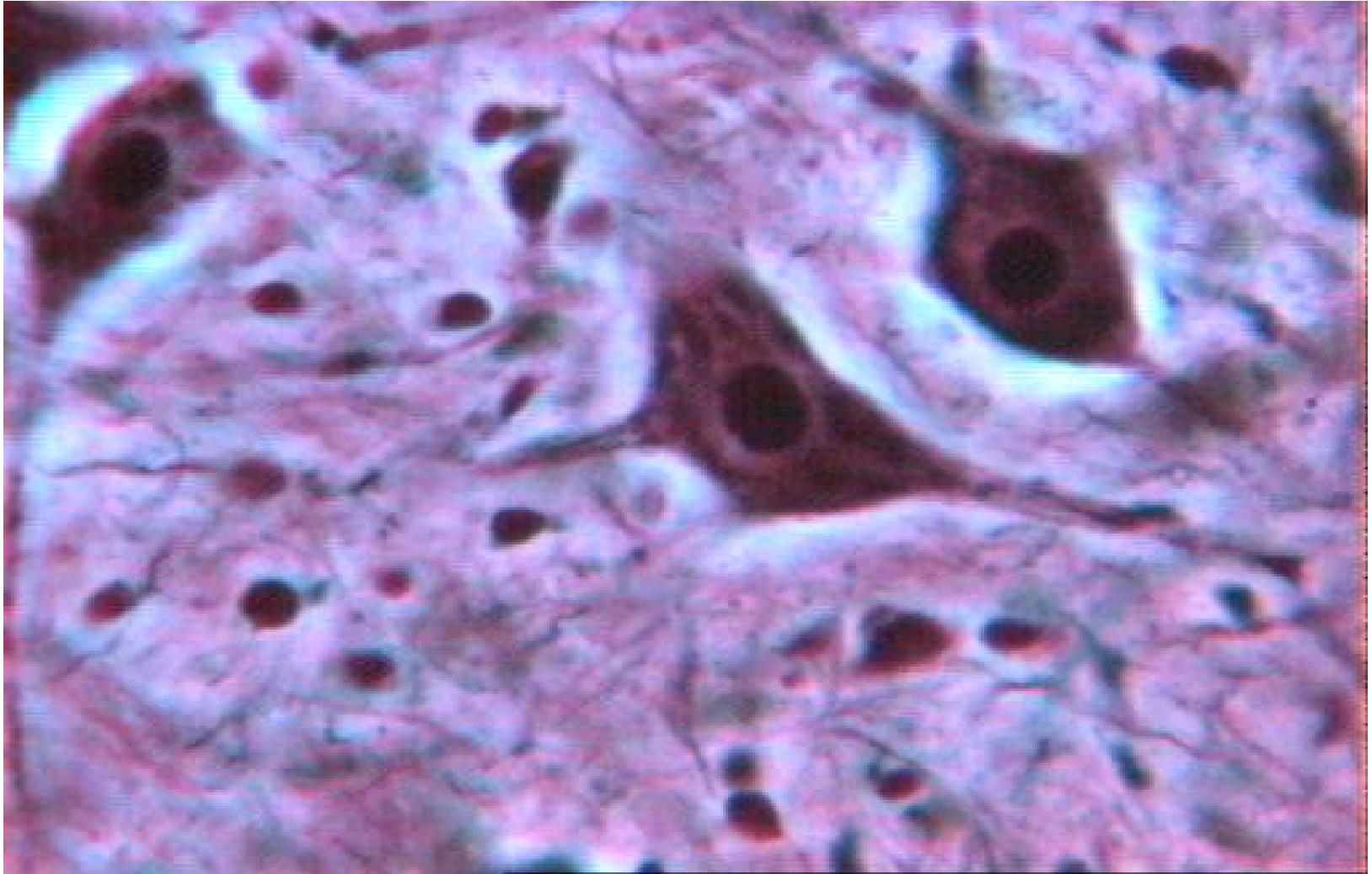
Tejido muscular estriado cardíaco (*ratón*)



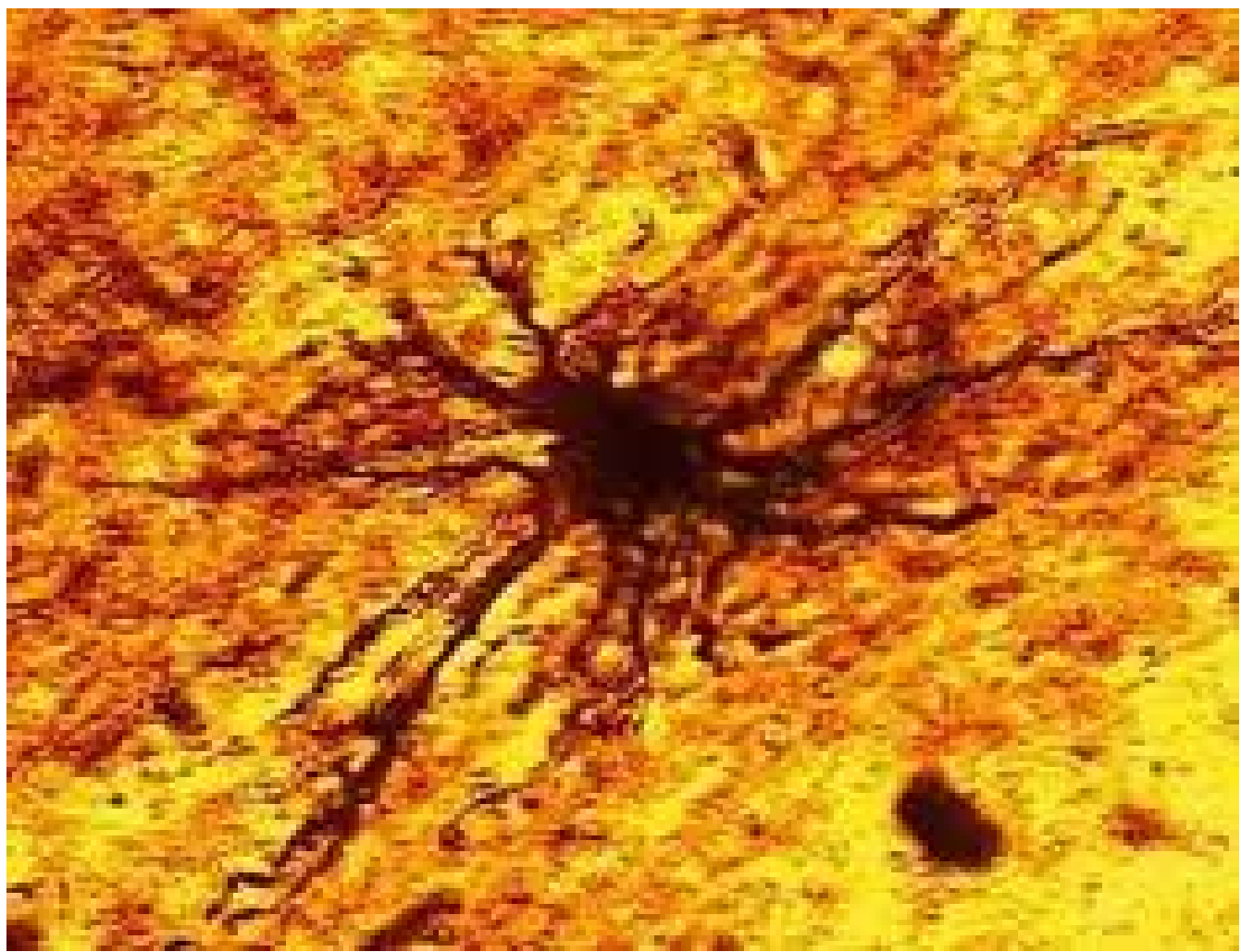


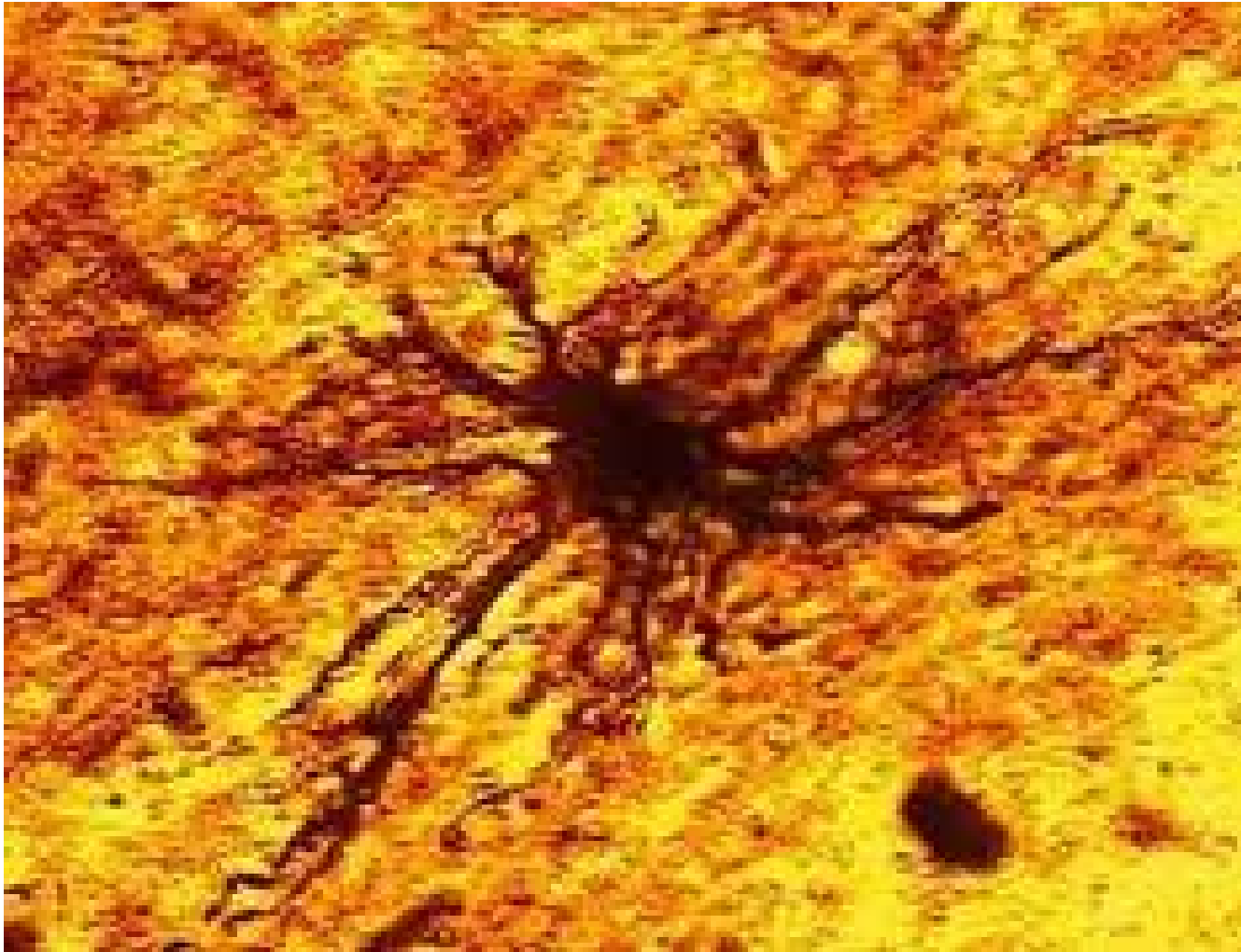
Tejido muscular liso (intestino delgado)





Tejido nervioso (médula espinal)





Células Glía (astrocito)

TEJIDOS VEGETALES



Tejido embrionario



Tejido parenquimático



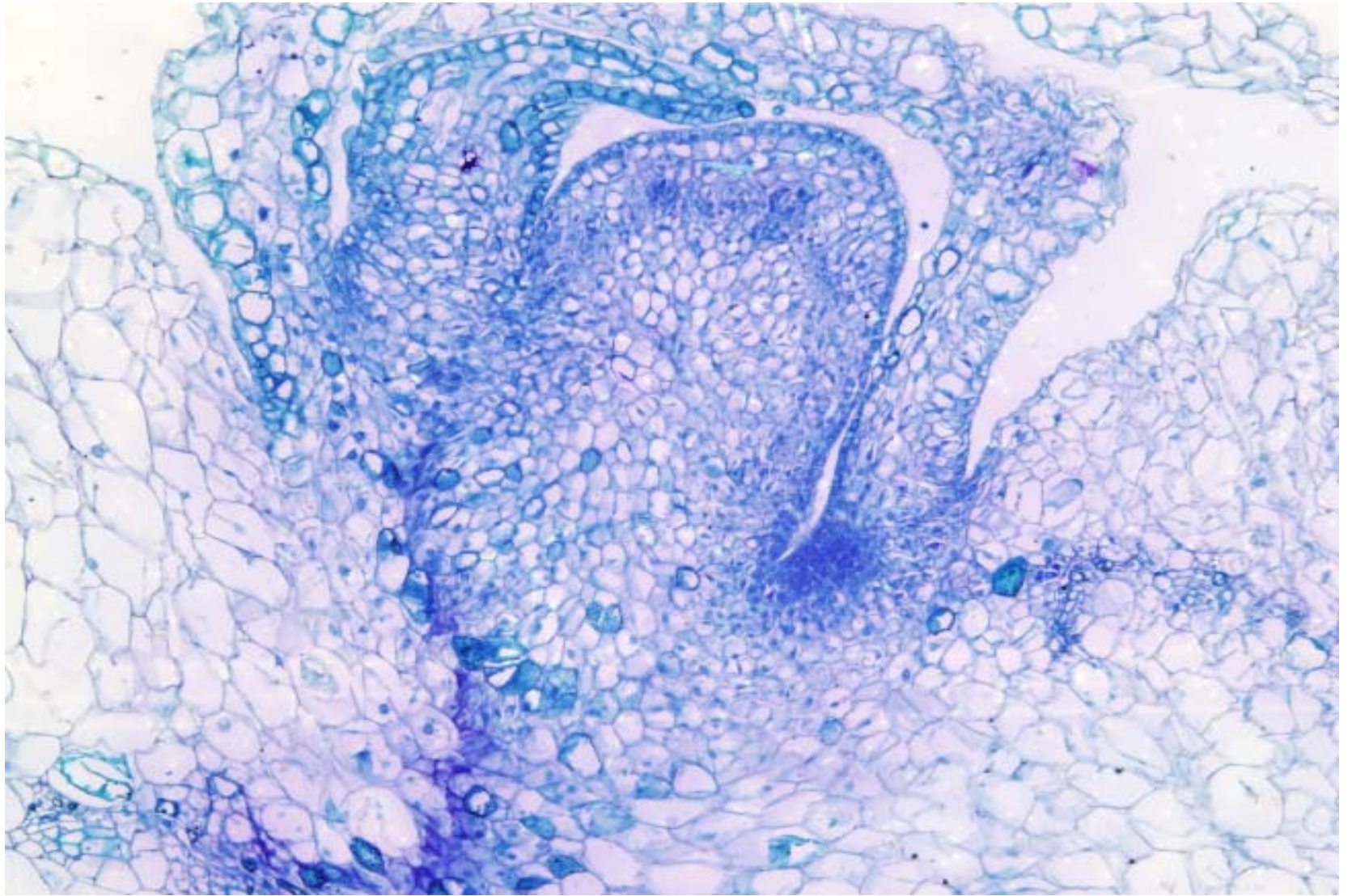
Tejido protector

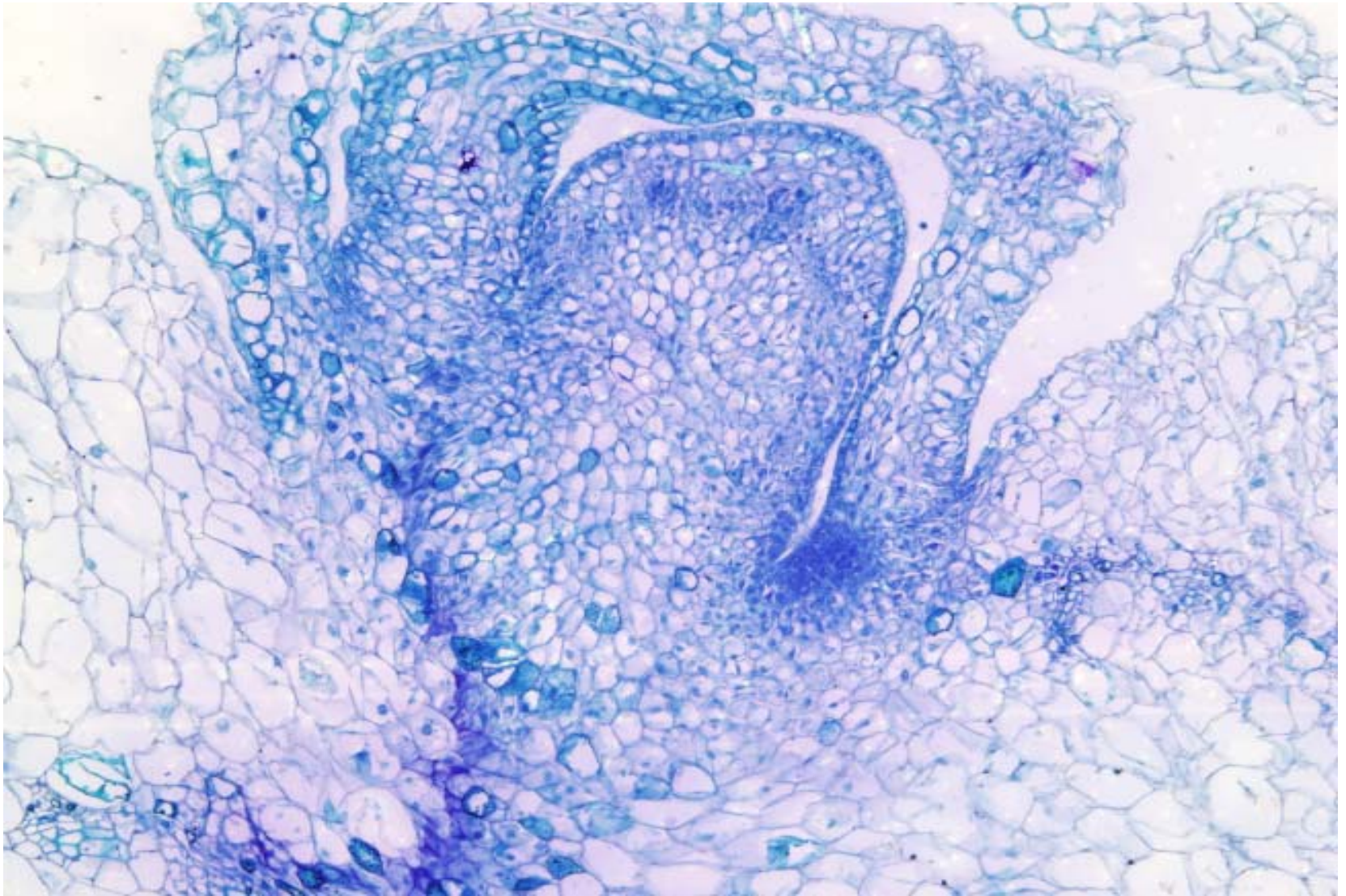


Tejido de sostén

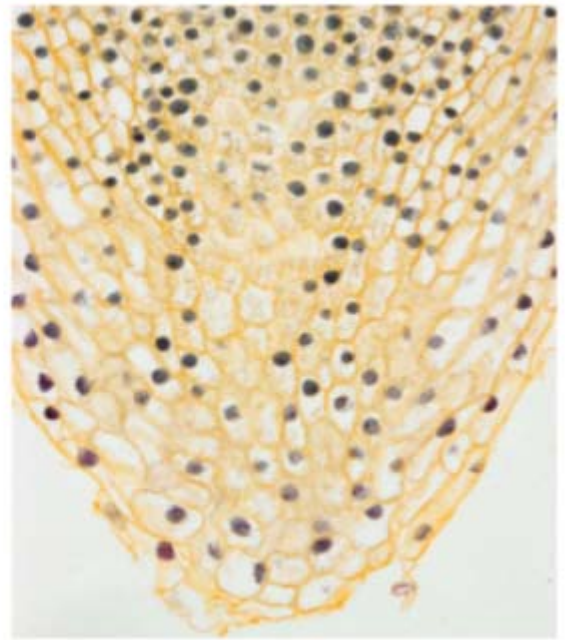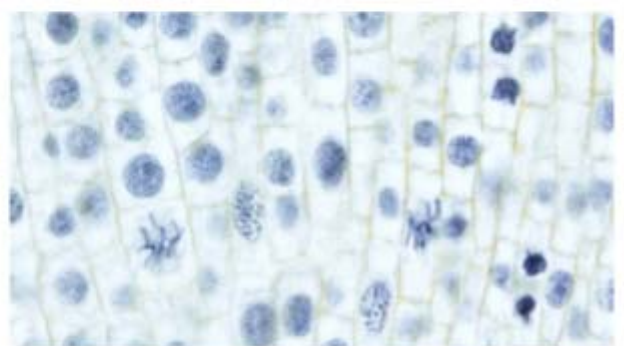
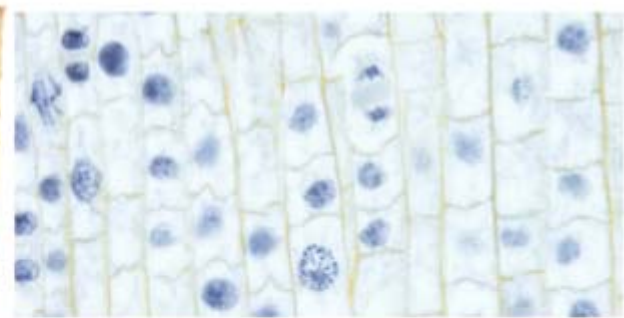



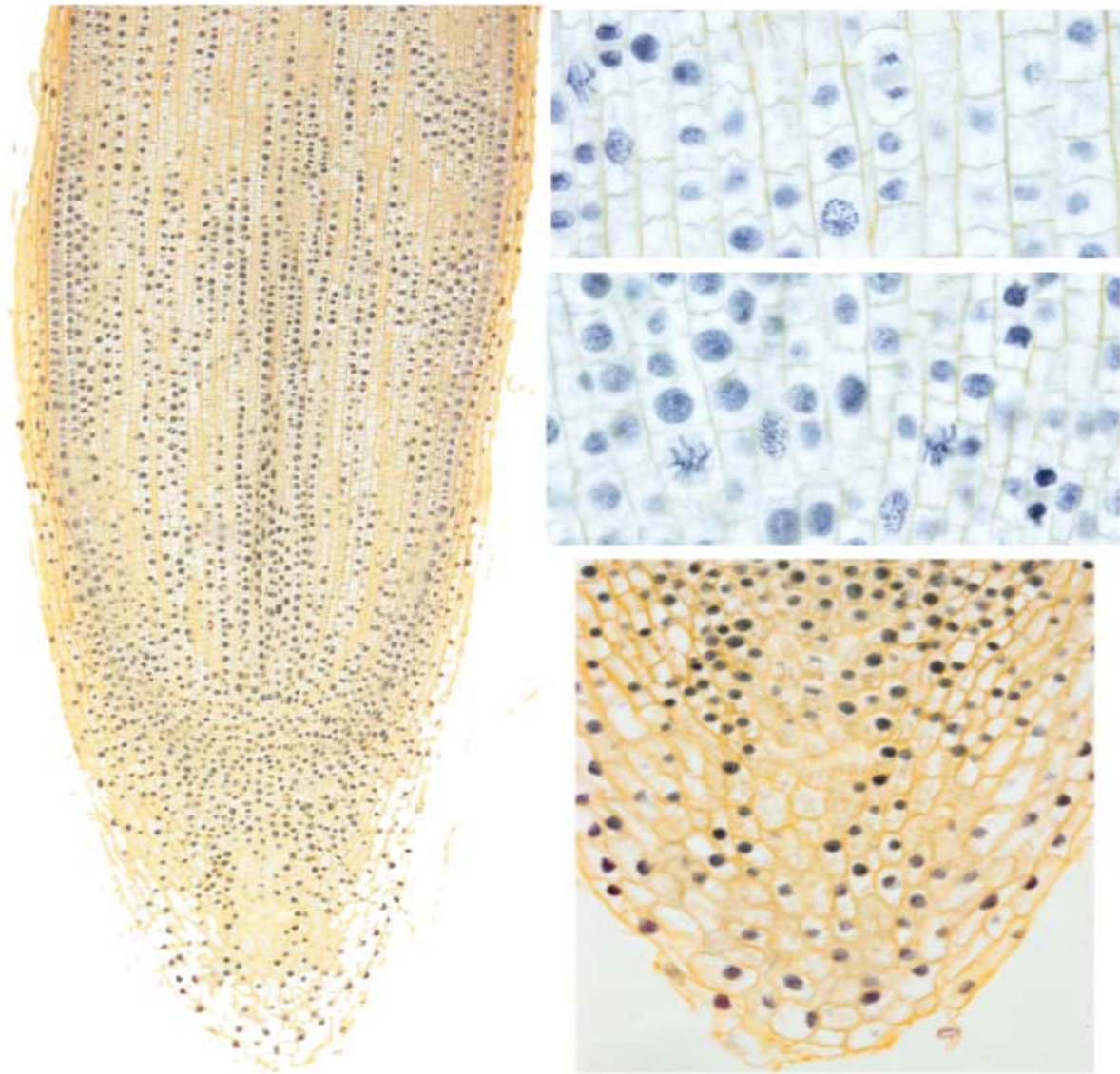
Tejido conductor



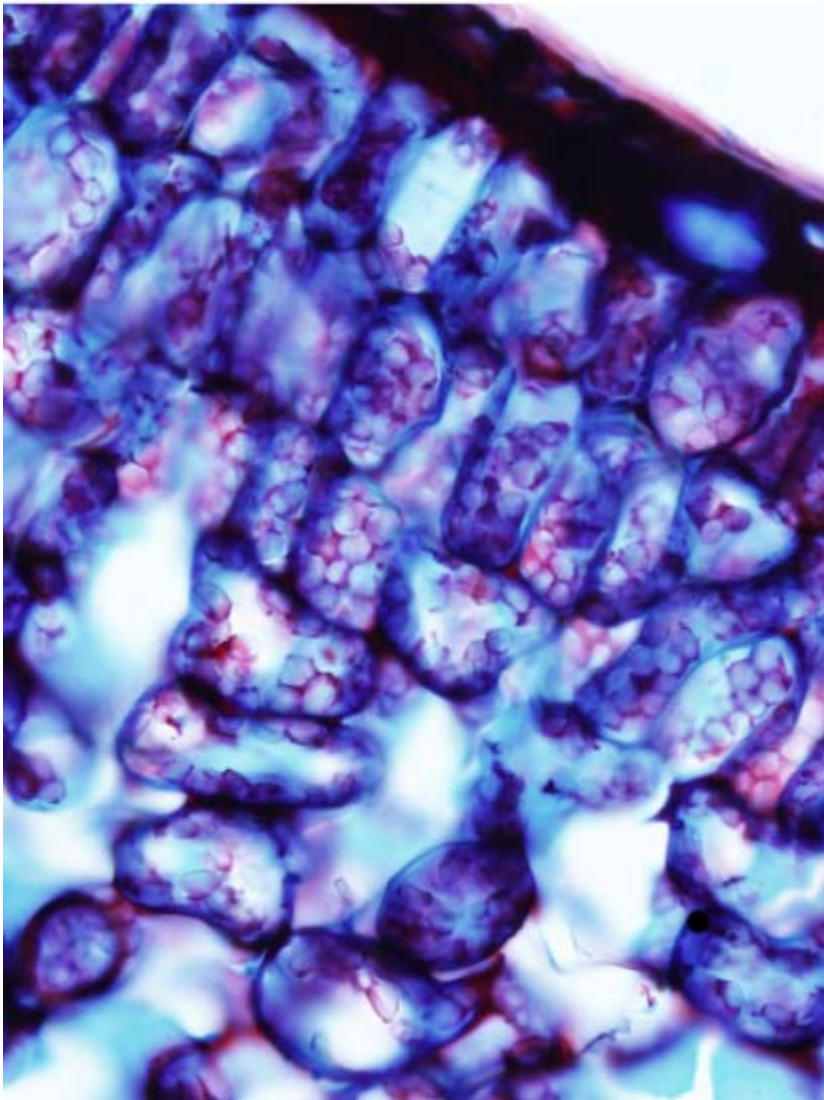


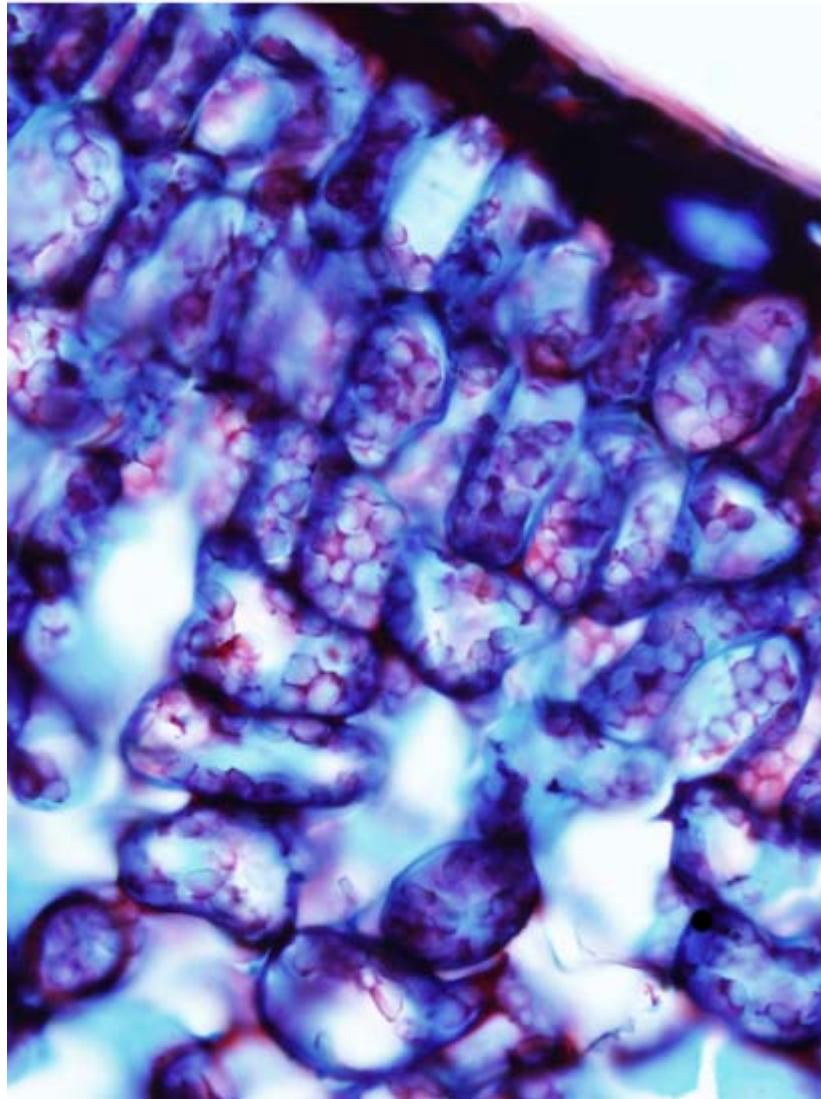
Meristemo apical (*tallo vid*)



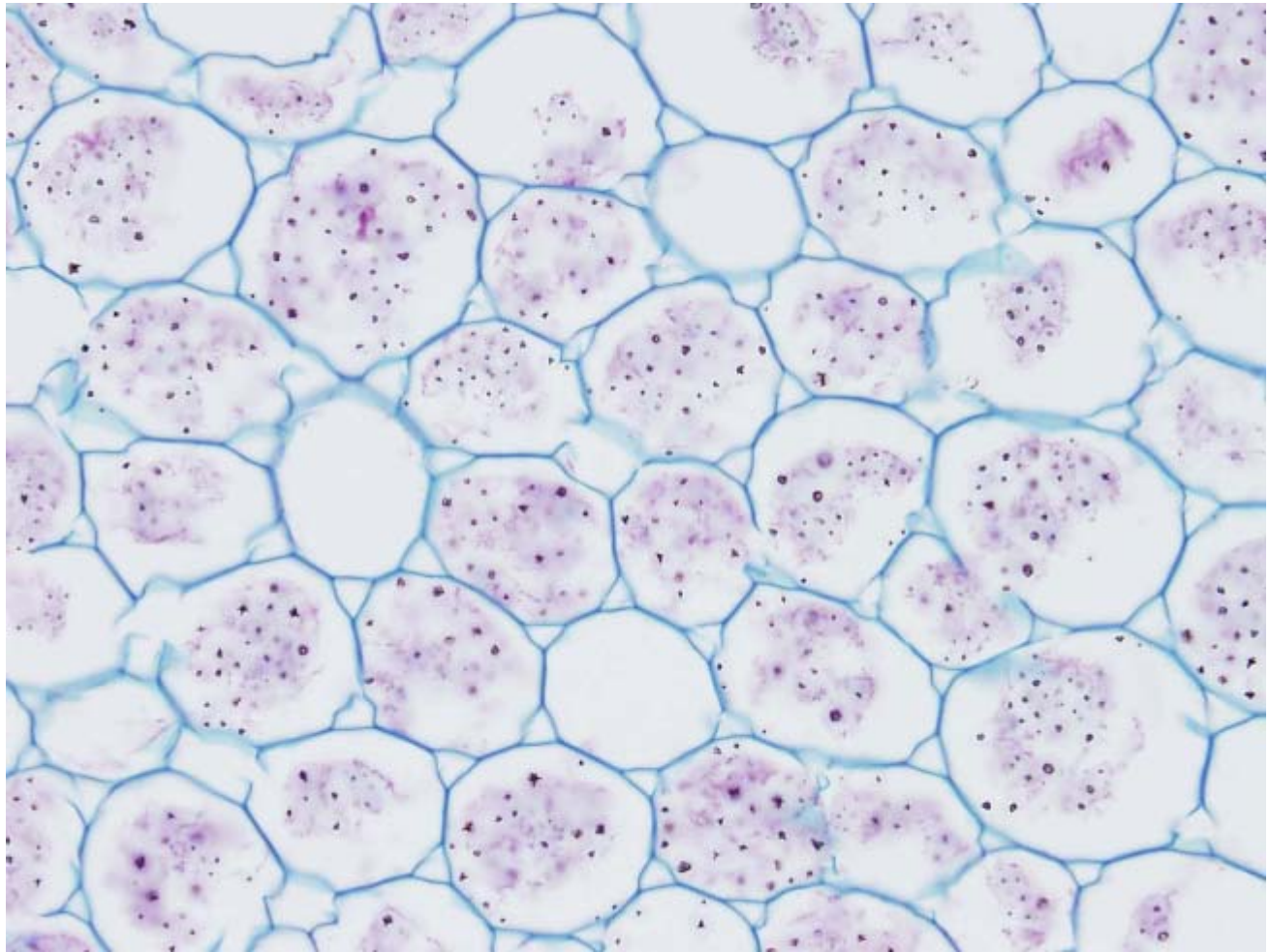


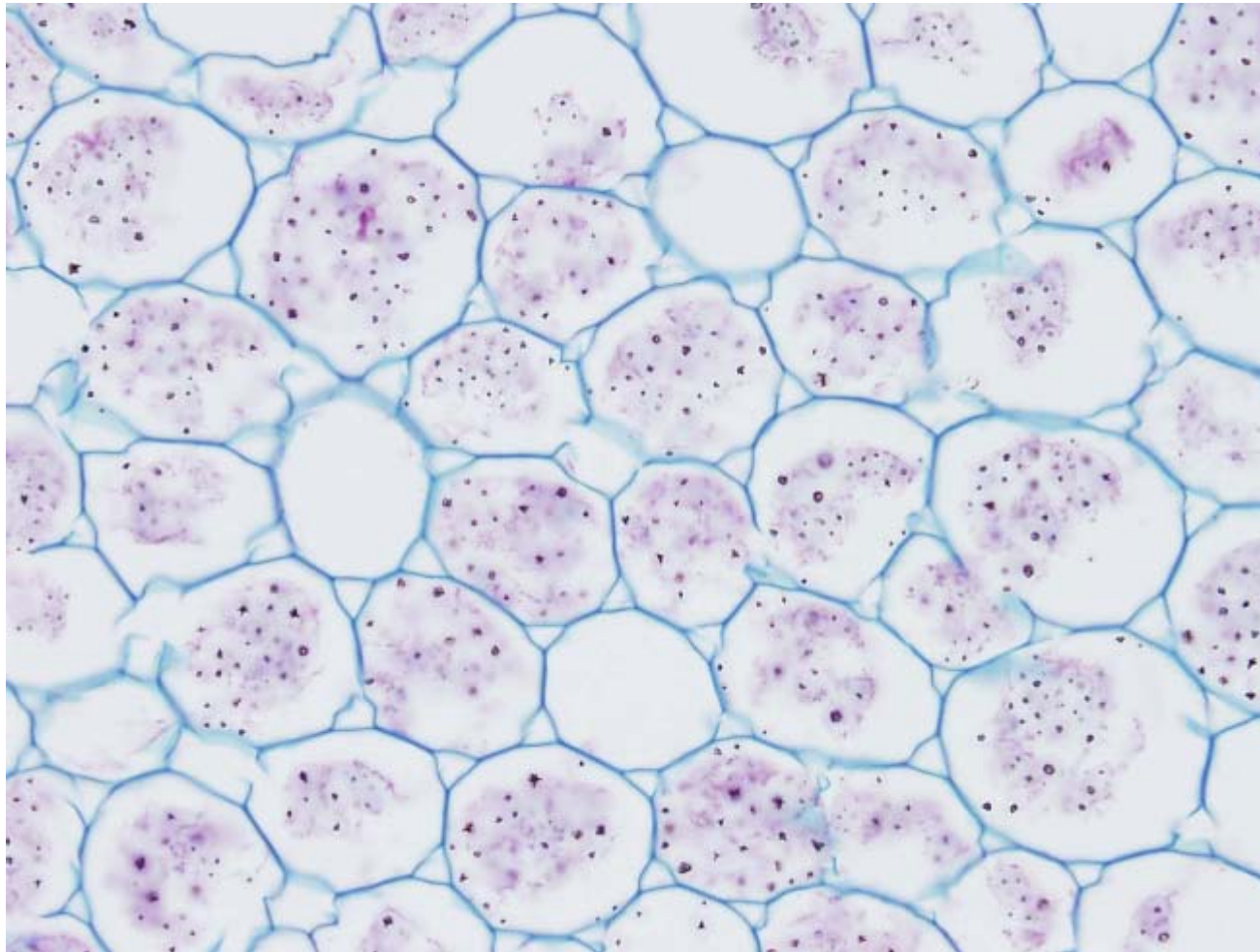
Meristemo radical (*raíz cebolla*)



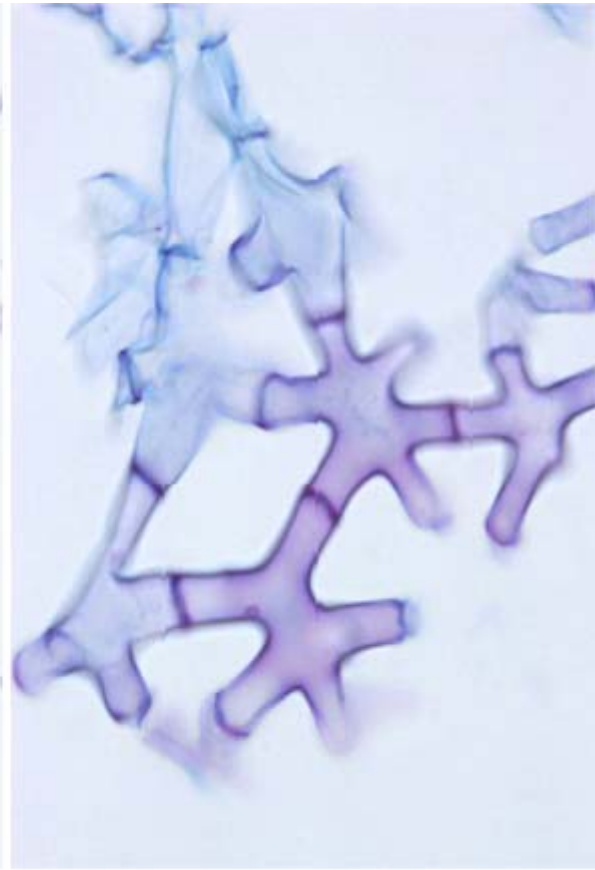
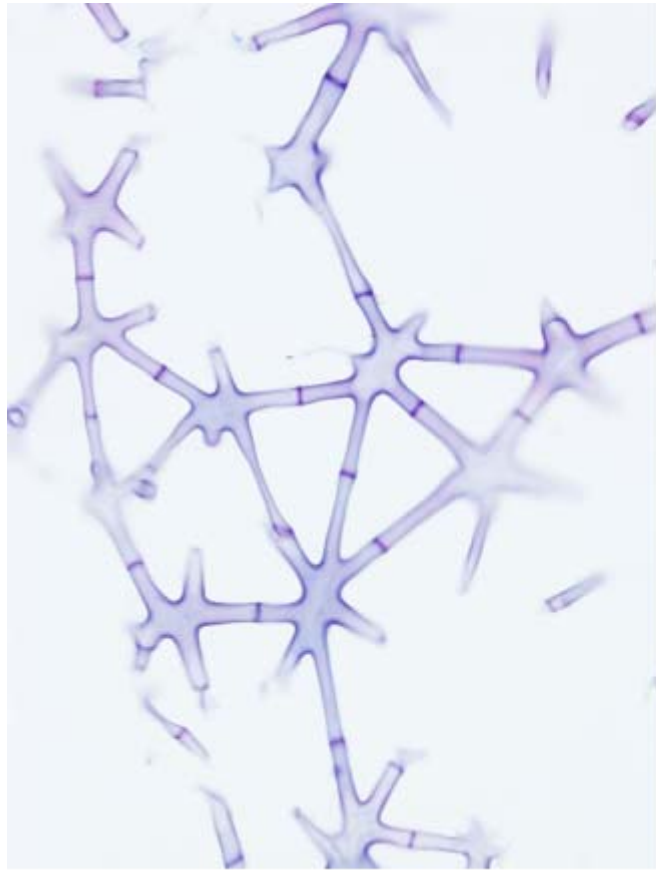


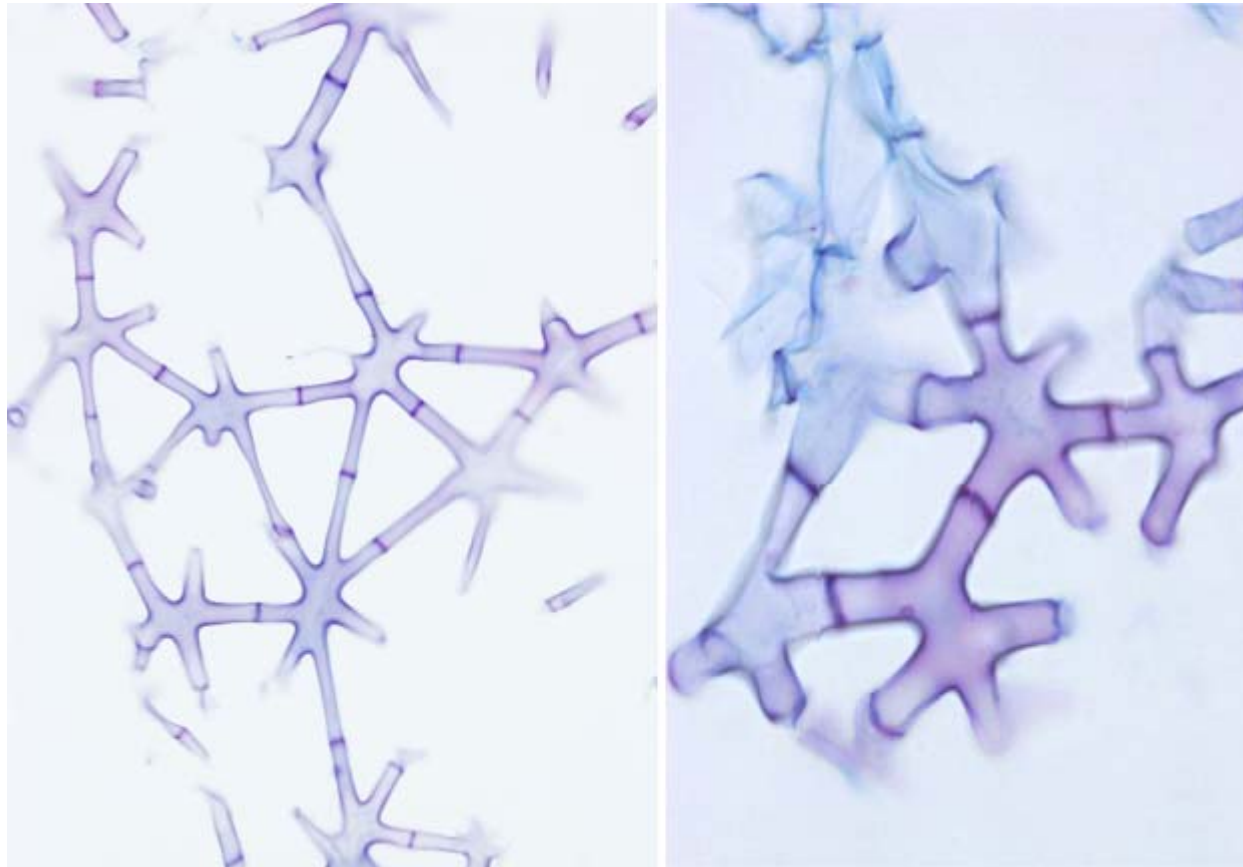
Parénquima clorofílico (*camelia*)







Parénquima de reserva (*botón de oro*)



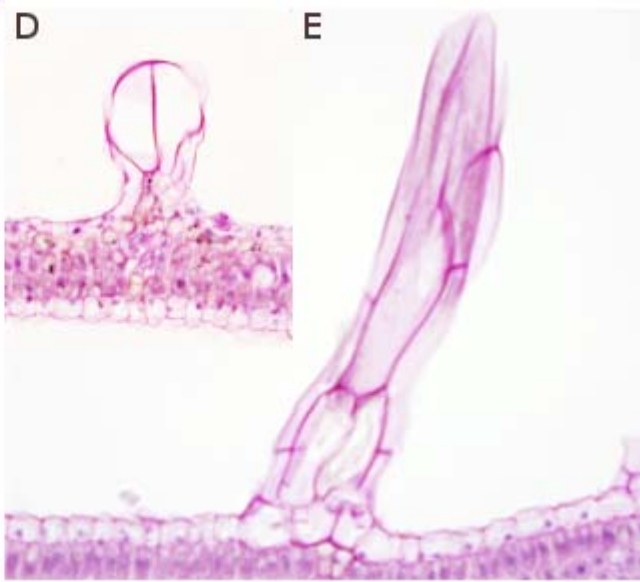
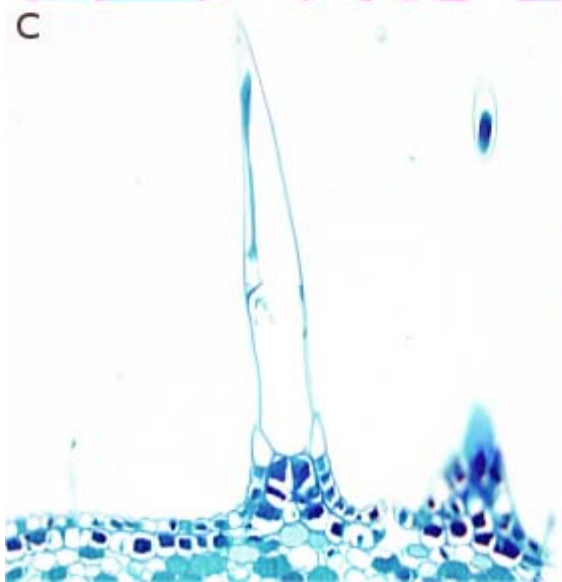
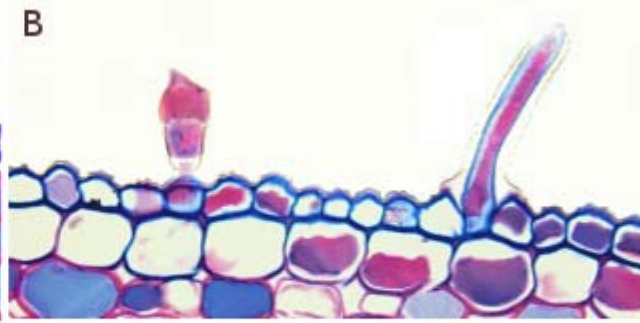
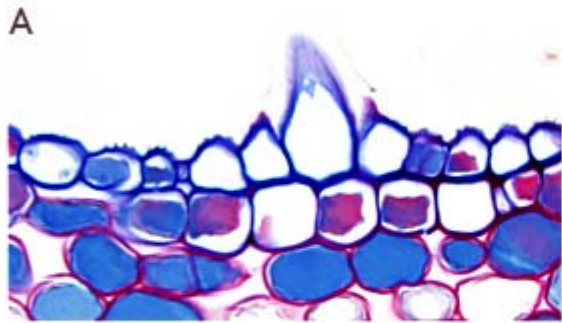


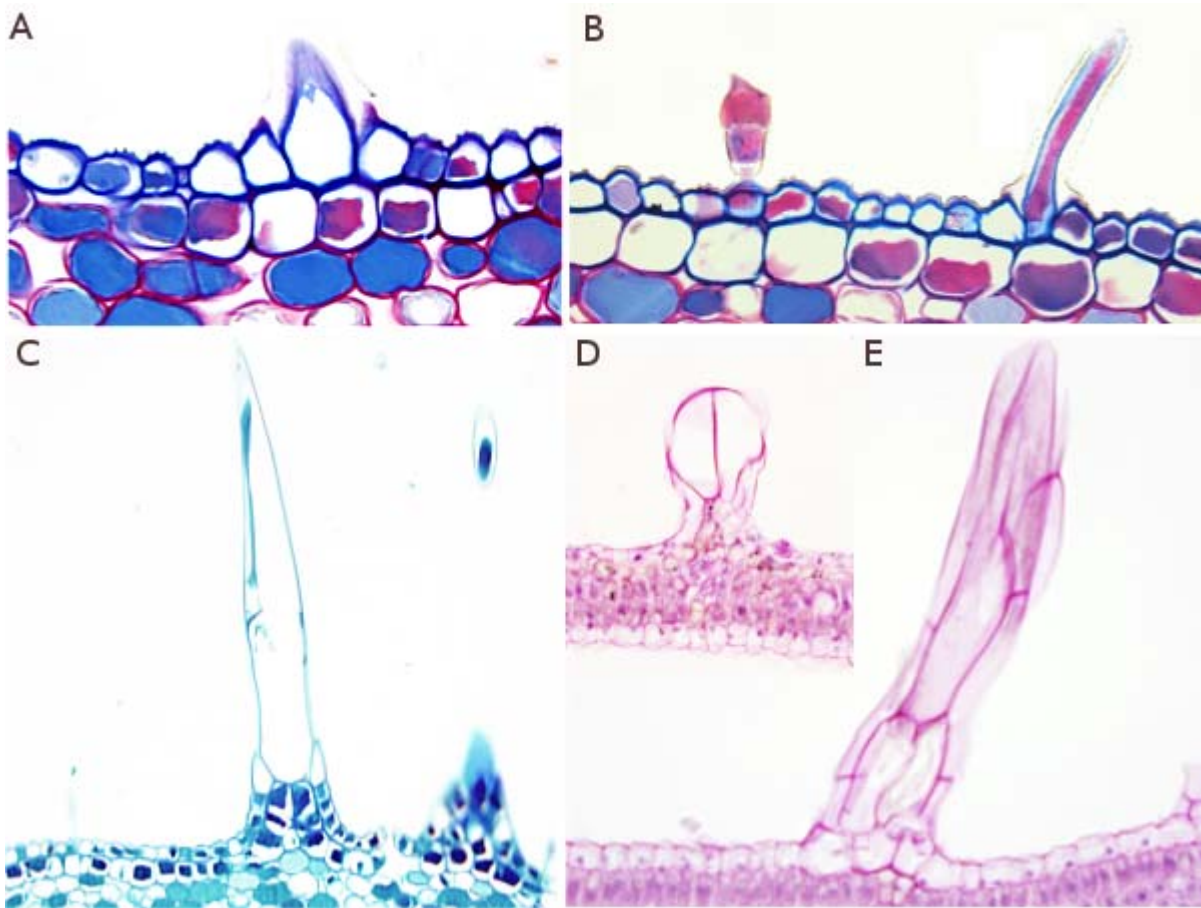
Parénquima aerífero (*junco*)





Tejido protector epidérmico (*estoma puerro*)

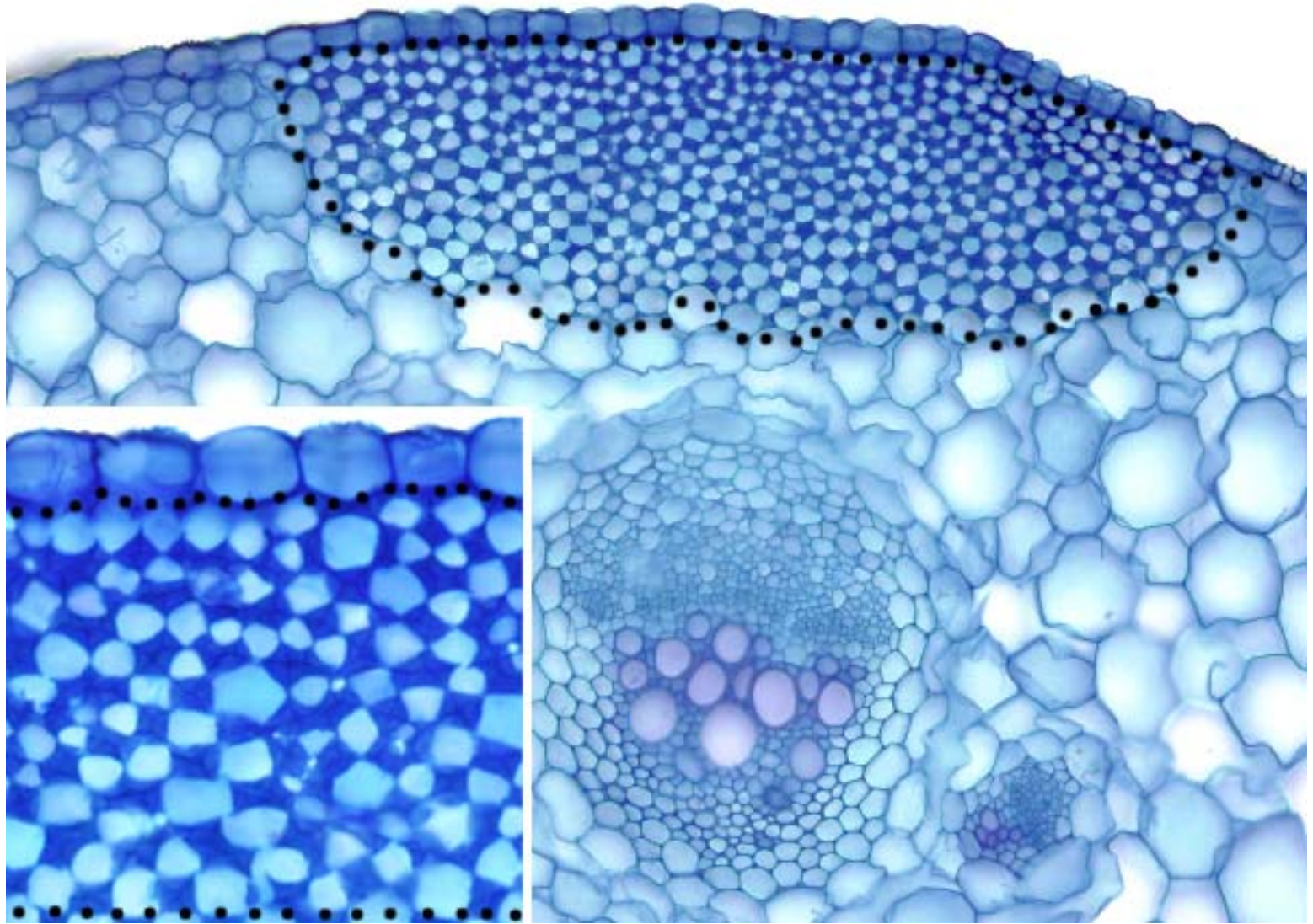


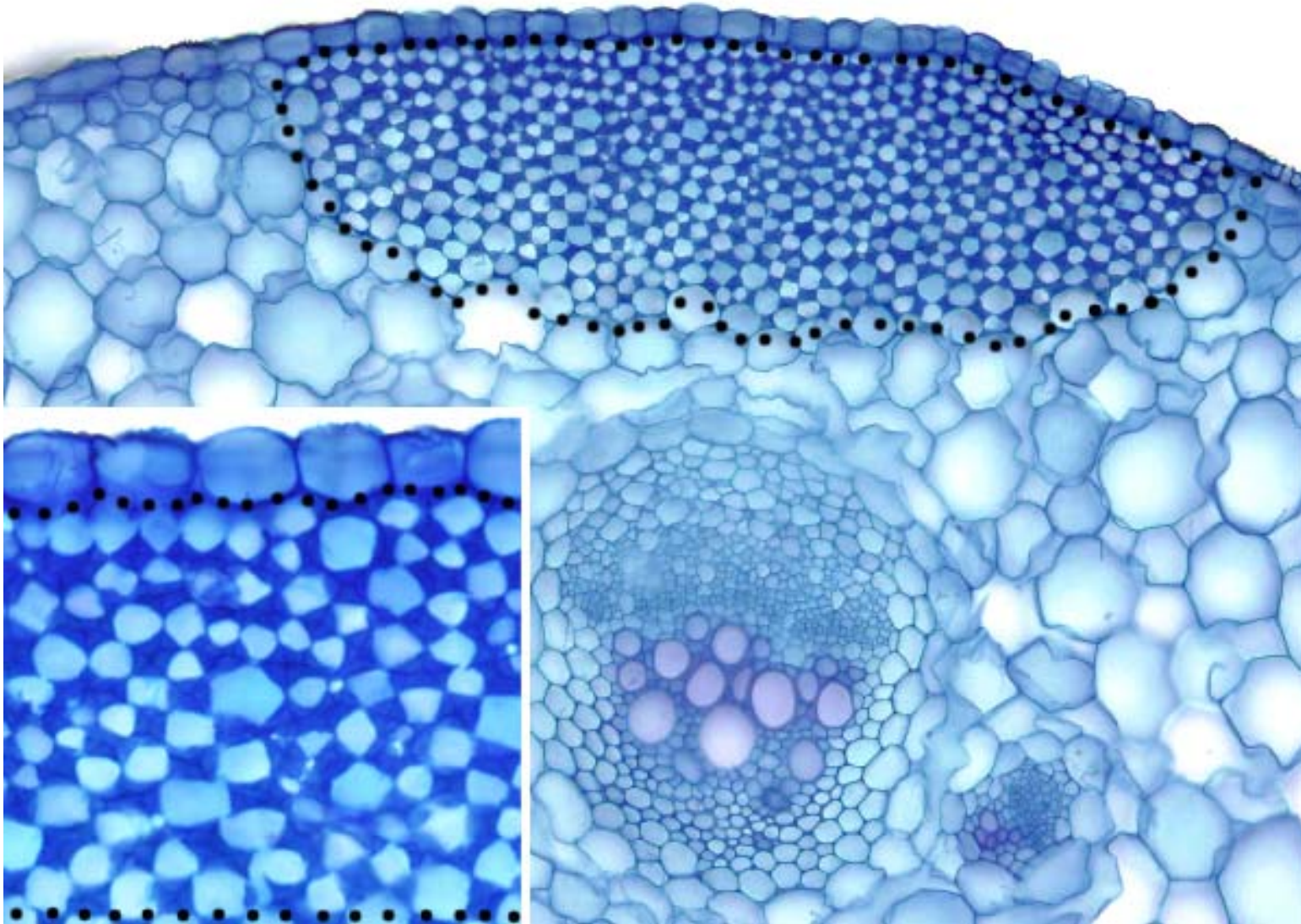


Tejido protector epidérmico (*tricoma malva*)

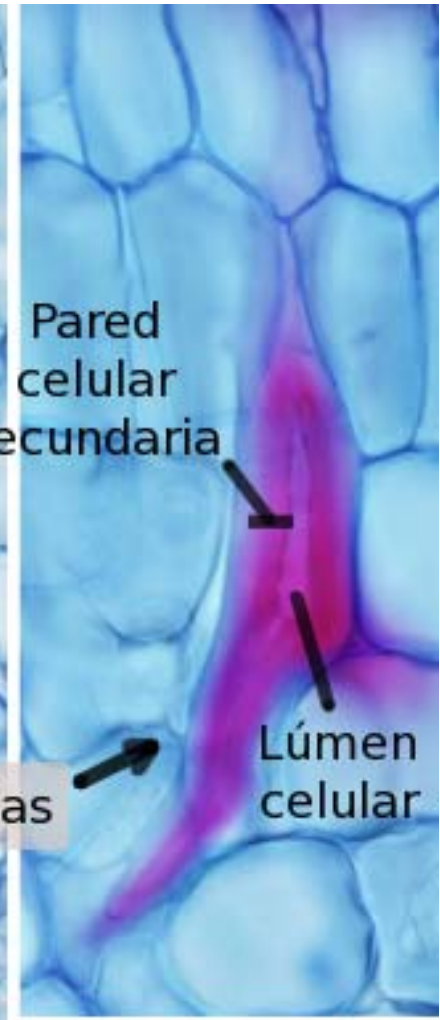
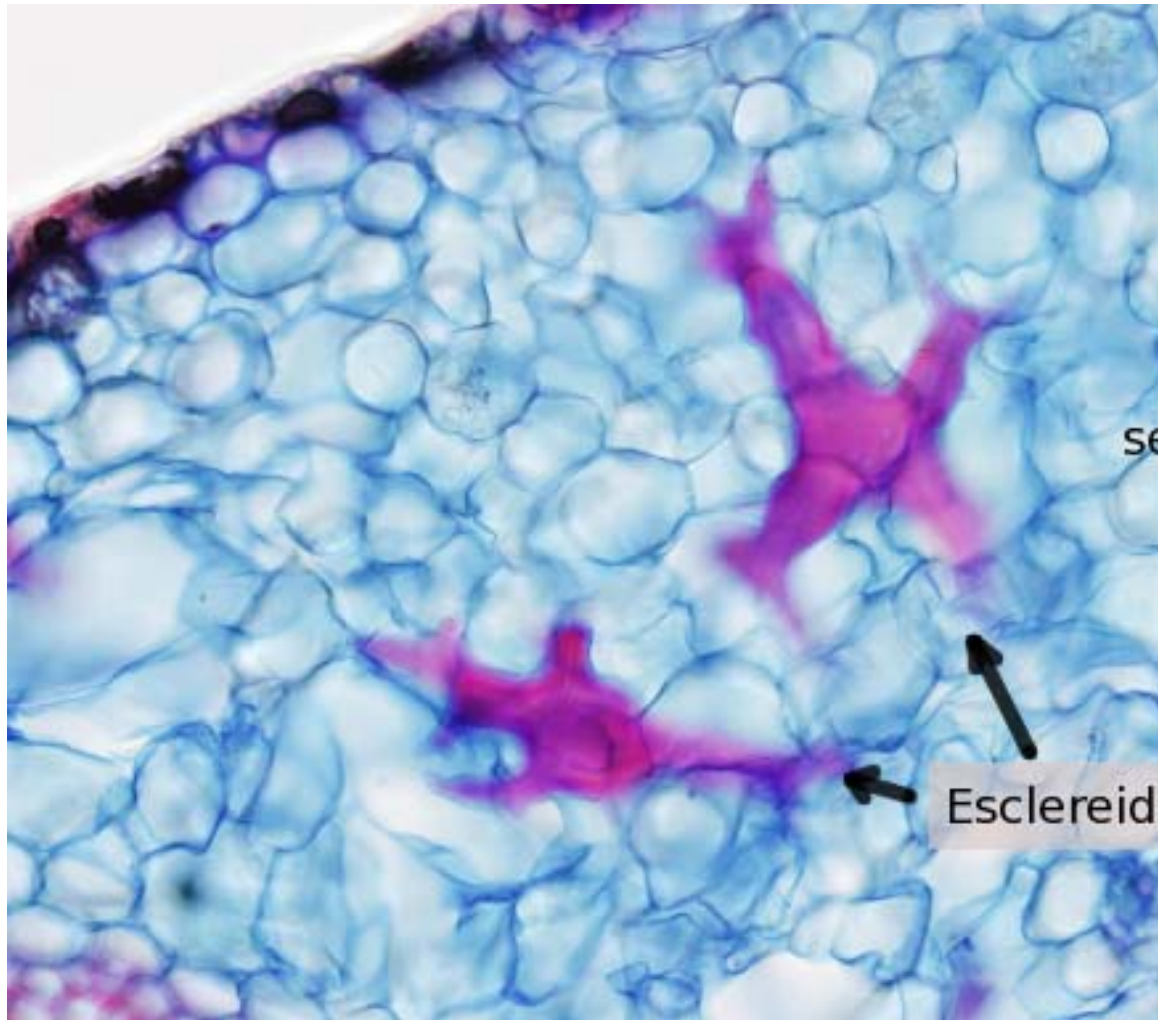


Tejido protector suberoso (*lenticela saúco*)





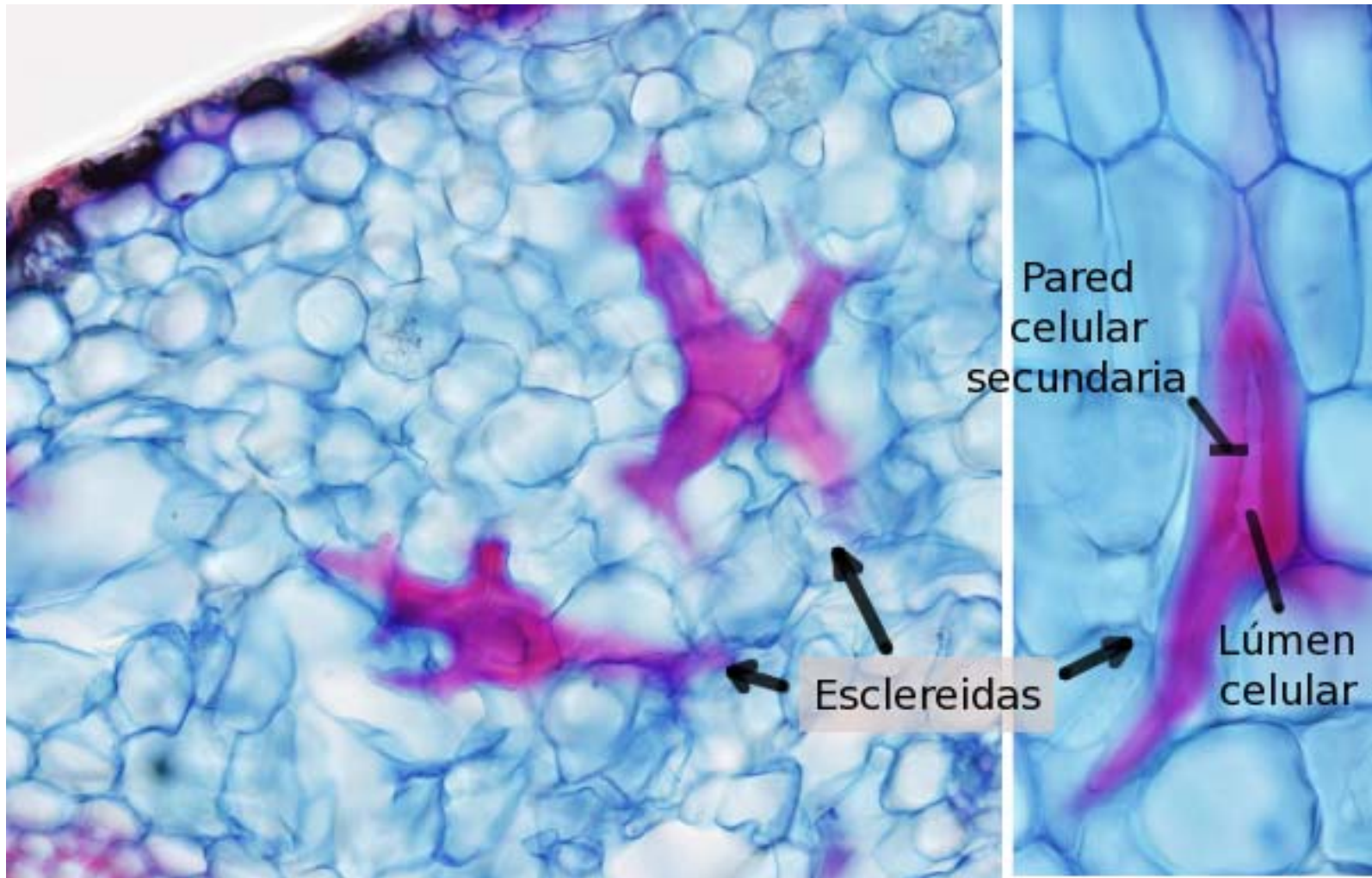
Tejido de sostén (*Colénquima hiedra*)



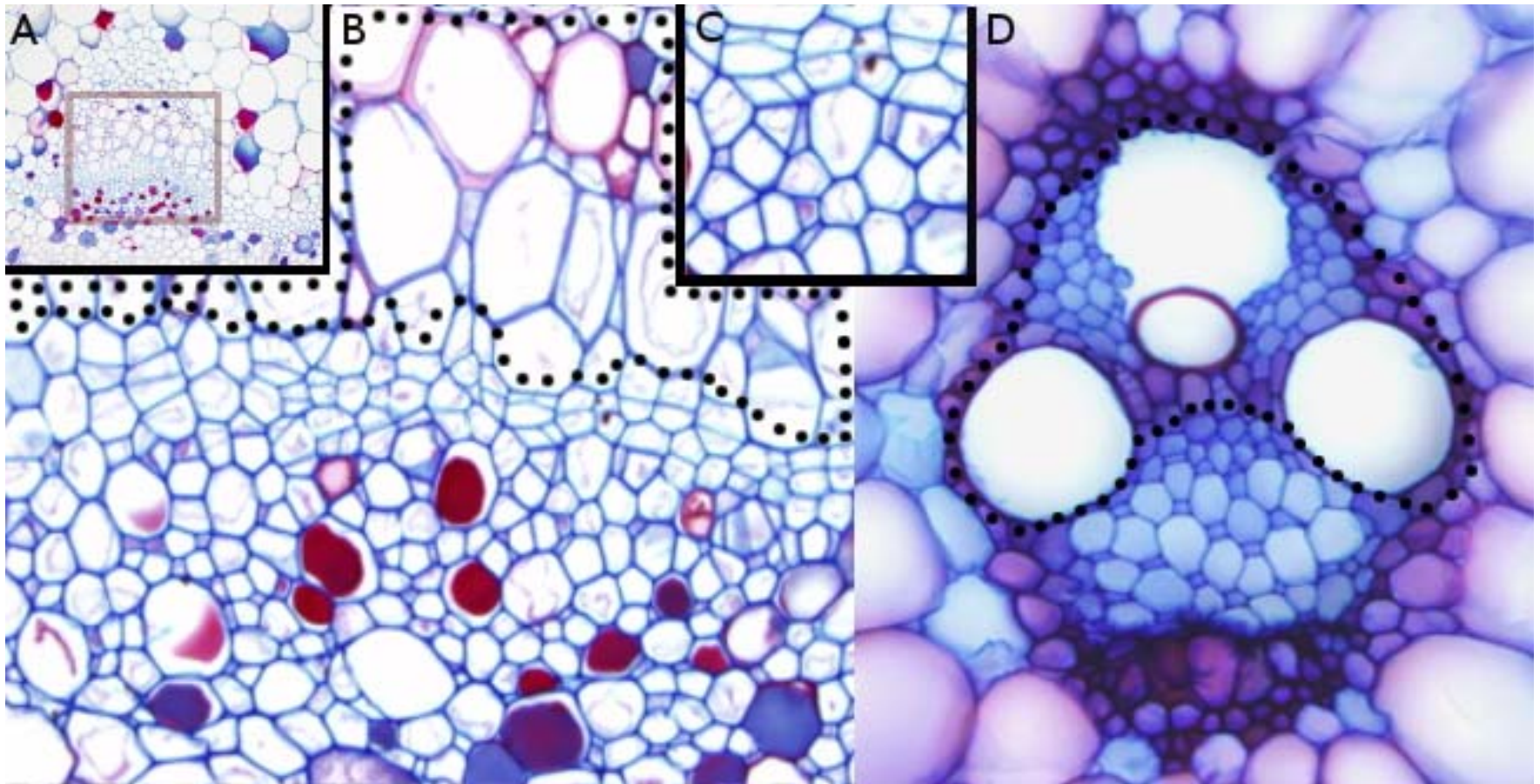
Pared celular secundaria

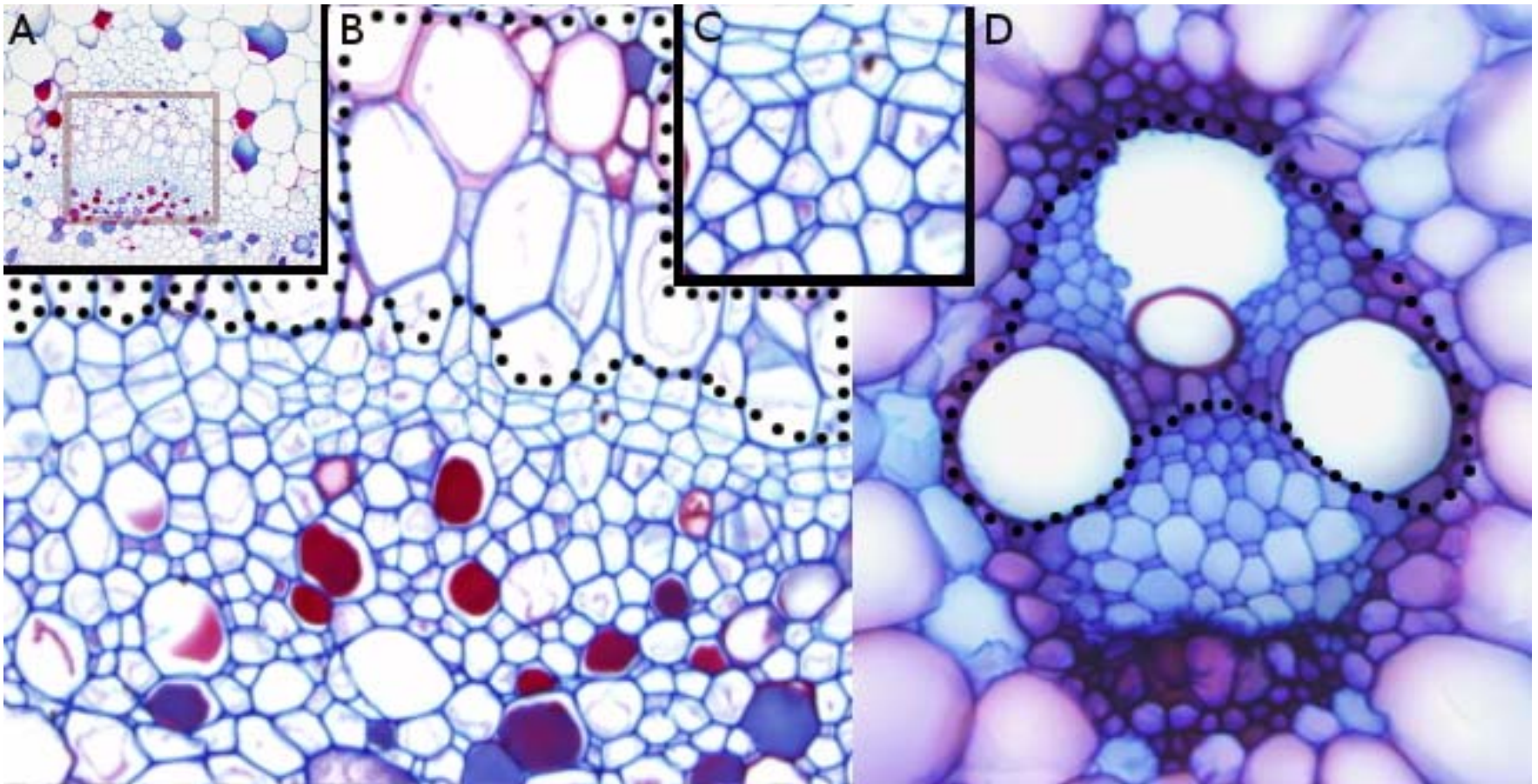
Lúmen celular

Esclereidas

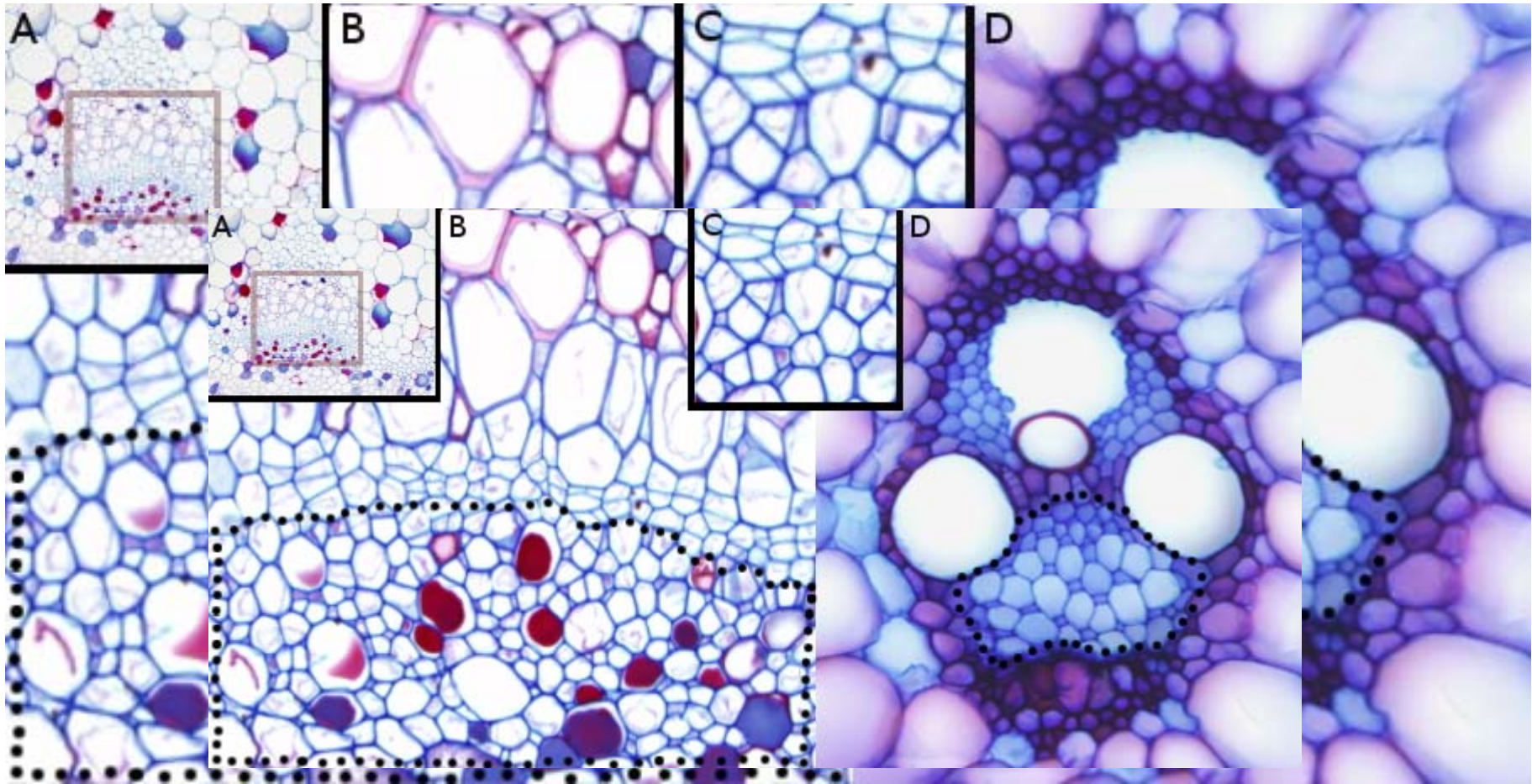


Tejido de sostén (*esclerénquima malva*)





Tejido conductor (*xilema maíz*)



Tejido conductor (*floema maíz*)